Ultrasound Use Helps Detect the Optimal Site for Insertion of a Radial Arterial Line in the Wrist Area

Muhammad H. Ibrahim MD DESA[1], Ahmed Awadghanem MD[2,3]
1) Department of Anesthesia and Critical Care, An-Najah National University Hospital.
2) Department of Radiology, An-Najah National University Hospital. 3) Faculty of Medicine and Health Sciences, An-Najah National University

Introduction

Radial artery catheters are commonly placed for continuous blood pressure monitoring, frequent arterial blood gas analysis, or frequent blood sampling for diagnostic testing. Radial artery cannulation can be challenging and ultrasound guidance has emerged as a valuable adjunct for the placement of radial artery catheters.

Case Report

71 years old male patient with ESRD on regular HD since 4 months, HTN and CHF (EF 35%) was admitted the hospital complaining of Right lower limb pain and swelling with cold Rt foot toes as a case of Rt lower limb symptomatic popliteal aneurysm (> 3cm) for Rt lower limb bypass. Pre-induction radial arterial line was attempted but failed after 3 trials.

Induction of anesthesia was done in a controlled manner using 50mg Propofol, 50mg rocuronium and 200 mcg Fentanyl

Endotracheal tube was inserted and after stabilizing the patient; left radial arterial line was attempted using the landmark technique with 30 degrees wrist flexion and insertion at the proximal crease. Radial pulse was easily palpable. First 2 trials using 20G angiocath failed to thread the catheter followed by 2 trials using vygon 20 G catheter with guidewire. Despite good pulsatile blood flow; the wire failed to thread through the cannula on both occasions. Upon departmental policy the ultrasound was used for insertion and it was noticed that the radial artery bifurcates 1 cm proximal to the proximal crease of the wrist to 2 vessels. Under ultrasound guidance, catheterization was attempted proximal to the radial artery bifurcation and the wire was threaded easily without resistance followed by insertion of the catheter using Seldinger technique.

Discussion

Current techniques used for radial artery cannulation include: puncturing the vessel and then using the Seldinger technique to advance the catheter over a guide- wire, puncturing the vessel and then directly advancing the catheter into the artery, a surgical cutdown to provide direct vessel visualization, use of Doppler ultrasound, and direct vessel visualization with 2-dimensional ultrasound guidance . Grey's Anatomy Textbook only mentioned small branches at the wrist " dorsal Carpal and first Dorsal Metacarpal branches which are small ones while in our case the artery bifurcated into 2 arteries of almost equal diameter few centimeters proximal to the radial styloid process. This bifurcation could be a reason for failed landmark technique for radial arterial cannulation and could be an added advantage of early utilization of the US for radial arterial cannulation.

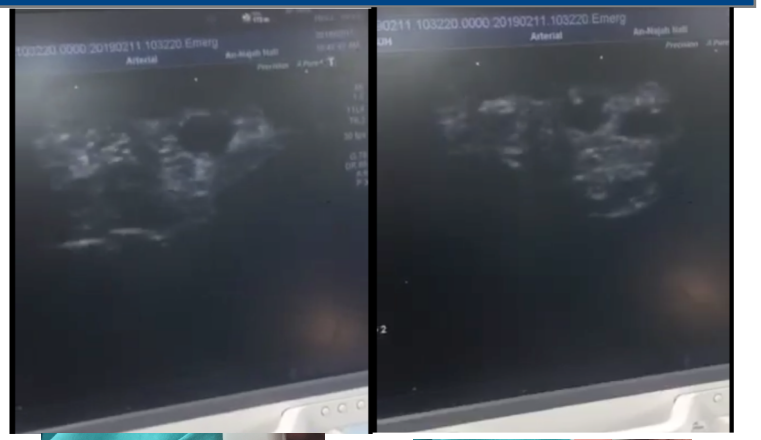

References

1. Respir Care 2016;61(3):383–388. © 2016 Daedalus Enterprises]
2. Gray, Henry. *Anatomy of the Human Body.* Philadelphia: Lea & Febiger, 1918; Bartleby.com, 2000. www.bartleby.com/107/