

World Journal of *Hepatology*

World J Hepatol 2020 July 27; 12(7): 332-412



REVIEW

- 332 Oxidative stress in alcohol-related liver disease
Tan HK, Yates E, Lilly K, Dhanda AD

ORIGINAL ARTICLE**Basic Study**

- 350 Ipragliflozin-induced improvement of liver steatosis in obese mice may involve sirtuin signaling
Suga T, Sato K, Ohyama T, Matsui S, Kobayashi T, Tojima H, Horiguchi N, Yamazaki Y, Kakizaki S, Nishikido A, Okamura T, Yamada M, Kitamura T, Uraoka T
- 363 Anti-inflammatory and anti-oxidant effects of aloe vera in rats with non-alcoholic steatohepatitis
Klaikeaw N, Wongphoom J, Werawatganon D, Chayanupatkul M, Siriviriyakul P

Observational Study

- 378 Non-alcoholic steatohepatitis and the risk of myocardial infarction: A population-based national study
Ghoneim S, Dhorepatil A, Shah AR, Ram G, Ahmad S, Kim C, Asaad I

META-ANALYSIS

- 389 Effect of zinc treatment on clinical outcomes in patients with liver cirrhosis: A systematic review and meta-analysis
Tan HK, Streeter A, Cramp ME, Dhanda AD

CASE REPORT

- 399 Diagnosis and management of hepatic artery in-stent restenosis after liver transplantation by optical coherence tomography: A case report
Galastri FL, Gilberto GM, Affonso BB, Valle LGM, Falsarella PM, Caixeta AM, Lima CA, Silva MJ, Pinheiro LL, Baptistella CDPA, Almeida MDD, Garcia RG, Wolosker N, Nasser F
- 406 Is right lobe liver graft without main right hepatic vein suitable for living donor liver transplantation?
Demyati K, Akbulut S, Cicek E, Dirican A, Koc C, Yilmaz S

ABOUT COVER

Editorial board member of *World Journal of Hepatology*. Koo Jeong Kang, MD, PhD, Professor, Division of HBP Surgery, Department of Surgery, Keimyung University Dong-San Hospital, Daegu, South Korea. As a hepatobiliary surgeon, he has been dedicated in hepatobiliary and pancreatic surgery including HCC, intrahepatic cholangiocarcinoma, hilar cholangiocarcinoma, cancer of gallbladder, pancreatic cancer and liver transplantation including LDLT, laparoscopic as well as open. Initially as a HBP surgeon, his research interests was hepatic ischemia/reperfusion injury to prevent hepatic injury both clinical but experimental research to establish safe liver surgeries. And he interested in the clinical significance of anatomical resection of the liver cancer, systematic segmentectomy or Glissonian pedicle approach according to the size and location of the tumor.

AIMS AND SCOPE

The primary aim of *World Journal of Hepatology (WJH, World J Hepatol)* is to provide scholars and readers from various fields of hepatology with a platform to publish high-quality basic and clinical research articles and communicate their research findings online.

WJH mainly publishes articles reporting research results and findings obtained in the field of hepatology and covering a wide range of topics including chronic cholestatic liver diseases, cirrhosis and its complications, clinical alcoholic liver disease, drug induced liver disease autoimmune, fatty liver disease, genetic and pediatric liver diseases, hepatocellular carcinoma, hepatic stellate cells and fibrosis, liver immunology, liver regeneration, hepatic surgery, liver transplantation, biliary tract pathophysiology, non-invasive markers of liver fibrosis, viral hepatitis.

INDEXING/ABSTRACTING

The *WJH* is now abstracted and indexed in PubMed, PubMed Central, Emerging Sources Citation Index (Web of Science), Scopus, China National Knowledge Infrastructure (CNKI), China Science and Technology Journal Database (CSTJ), and Superstar Journals Database.

RESPONSIBLE EDITORS FOR THIS ISSUE

Electronic Editor: *Li-Li Wang*, Production Department Director: *Yun-Xiaojuan Wu*, Editorial Office Director: *Jiu-Ping Yan*.

NAME OF JOURNAL

World Journal of Hepatology

ISSN

ISSN 1948-5182 (online)

LAUNCH DATE

October 31, 2009

FREQUENCY

Monthly

EDITORS-IN-CHIEF

Nikolaos Pylsopoulos, Ke-Qin Hu, Koo Jeong Kang

EDITORIAL BOARD MEMBERS

<https://www.wjgnet.com/1948-5182/editorialboard.htm>

PUBLICATION DATE

July 27, 2020

COPYRIGHT

© 2020 Baishideng Publishing Group Inc

INSTRUCTIONS TO AUTHORS

<https://www.wjgnet.com/bpg/gerinfo/204>

GUIDELINES FOR ETHICS DOCUMENTS

<https://www.wjgnet.com/bpg/GerInfo/287>

GUIDELINES FOR NON-NATIVE SPEAKERS OF ENGLISH

<https://www.wjgnet.com/bpg/gerinfo/240>

PUBLICATION ETHICS

<https://www.wjgnet.com/bpg/GerInfo/288>

PUBLICATION MISCONDUCT

<https://www.wjgnet.com/bpg/gerinfo/208>

ARTICLE PROCESSING CHARGE

<https://www.wjgnet.com/bpg/gerinfo/242>

STEPS FOR SUBMITTING MANUSCRIPTS

<https://www.wjgnet.com/bpg/GerInfo/239>

ONLINE SUBMISSION

<https://www.f6publishing.com>

Is right lobe liver graft without main right hepatic vein suitable for living donor liver transplantation?

Khaled Demyati, Sami Akbulut, Egemen Cicek, Abuzer Dirican, Cemalettin Koc, Sezai Yilmaz

ORCID number: Khaled Demyati 0000-0002-9591-2664; Sami Akbulut 0000-0002-6864-7711; Egemen Cicek 0000-0003-2691-7418; Abuzer Dirican 0000-0002-8647-3268; Cemalettin Koc 0000-0002-5676-6772; Sezai Yilmaz 0000-0002-8044-0297.

Author contributions: Akbulut S, Koc C and Cicek E designed the report; Akbulut S, and Dirican A performed surgical procedures, Cicek E and Akbulut S collected the patient's clinical data; Akbulut S, Demyati K and Yilmaz S analyzed the data and wrote the paper.

Informed consent statement: The patients involved in this study gave their informed written consent prior to study enrollment, authorizing the use and disclosure of protected health information.

Conflict-of-interest statement: The authors declare that they have no conflict of interest.

CARE Checklist (2016) statement: The authors have read the CARE Checklist (2016), and the manuscript was prepared and revised according to the CARE Checklist (2016).

Open-Access: This article is an open-access article that was selected by an in-house editor and fully peer-reviewed by external

Khaled Demyati, Sami Akbulut, Egemen Cicek, Abuzer Dirican, Cemalettin Koc, Sezai Yilmaz, Department of Surgery and Liver Transplant Institute, Inonu University Faculty of Medicine, Malatya 44280, Turkey

Khaled Demyati, An-Najah National University Hospital, An-Najah National University, Nablus 11941, Palestine

Corresponding author: Sami Akbulut, MD, Associate Professor, Department of Surgery and Liver Transplant Institute, Inonu University Faculty of Medicine, Elazig Yolu 10. Km, Malatya 44280, Turkey. akbulutsami@gmail.com

Abstract

BACKGROUND

Since the first living donor liver transplantation (LDLT) was performed by Raia and colleagues in December 1988, LDLT has become the gold standard treatment in countries where cadaveric organ donation is not sufficient. Adequate hepatic venous outflow reconstruction in LDLT is essential to prevent graft congestion and its complications including graft loss. However, this can be complex and technically demanding especially in the presence of complex variations and congenital anomalies in the graft hepatic veins.

CASE SUMMARY

Herein, we aimed to present two cases who underwent successful right lobe LDLT using a right lobe liver graft with rudimentary or congenital absence of the right hepatic vein and describe the utility of a common large opening drainage model in such complex cases.

CONCLUSION

Thanks to this venous reconstruction model, none of the patients developed postoperative complications related to venous drainage. Our experience with venous drainage reconstruction models shows that congenital variations in the hepatic venous structure of living liver donors are not absolute contraindications for LDLT.

Key words: Living donor liver transplantation; Congenital-absence of right hepatic vein; Common large opening drainage model; Case report

©The Author(s) 2020. Published by Baishideng Publishing Group Inc. All rights reserved.

reviewers. It is distributed in accordance with the Creative Commons Attribution NonCommercial (CC BY-NC 4.0) license, which permits others to distribute, remix, adapt, build upon this work non-commercially, and license their derivative works on different terms, provided the original work is properly cited and the use is non-commercial. See: <http://creativecommons.org/licenses/by-nc/4.0/>

Received: March 9, 2020

Peer-review started: March 9, 2020

First decision: April 3, 2020

Revised: May 26, 2020

Accepted: May 28, 2020

Article in press: May 28, 2020

Published online: July 27, 2020

P-Reviewer: Akamatsu N, Yi PS, Zheng H

S-Editor: Zhang L

L-Editor: Webster JR

E-Editor: Ma YJ



Core tip: In this study, we aimed to present two cases who underwent successful right lobe living donor liver transplantation using a right lobe liver graft with rudimentary or congenital absence of the right hepatic vein and describe the utility of a common large opening drainage model in such complex cases. Thanks to this venous reconstruction model, none of the patients developed postoperative complications related to venous drainage.

Citation: Demyati K, Akbulut S, Cicek E, Dirican A, Koc C, Yilmaz S. Is right lobe liver graft without main right hepatic vein suitable for living donor liver transplantation? *World J Hepatol* 2020; 12(7): 406-412

URL: <https://www.wjgnet.com/1948-5182/full/v12/i7/406.htm>

DOI: <https://dx.doi.org/10.4254/wjh.v12.i7.406>

INTRODUCTION

Since the first successful liver transplantation (LT) performed in 1967, LT has become the gold standard treatment for many liver diseases in adult and pediatric patients^[1]. In socioculturally developed western countries, most of the liver graft requirements are provided from the cadaveric organ pool, while in Asian and Middle Eastern countries, a significant portion of the organ requirements are provided from the living donor pool^[1,2]. In deceased donor liver transplantation, whole size liver graft is harvested with the inferior vena cava (IVC) and then venous anastomosis can be performed easily between the IVC of the liver graft and IVC of the recipient using conventional, piggyback, or modified piggyback techniques^[1,2]. In contrast, variations in the vascular structure of the liver graft obtained from a living liver donor (LLD) cause difficulties during vascular reconstruction in LDLT, especially hepatic venous reconstruction. Venous drainage of the right lobe (RL) is more complex compared to the left lobe of the liver. To both benefit from liver graft optimally and avoid congestion-related complications, all large venous structures including inferior right hepatic vein (IRHV), segment 5 vein (V5) and segment 8 vein (V8) should be integrated into the venous drainage system^[3]. In other words, meticulous assessment of the vascular structures of the LLD candidates by preoperative radiological instruments and thus identification of variations is critical for both LLDs safety and planning of graft implantation techniques.

To evaluate the hepatic vascular structures of LLD candidates, Doppler ultrasonography (US), multidetector computed tomography (MDCT) and, if necessary, conventional hepatic angiography are the most commonly used techniques^[2]. Variations detected in the liver vascular anatomy of the potential LLD candidates either result in rejecting the candidate or the surgical team considers alternative surgical techniques such as various venous drainage models.

Congenital absence of the right hepatic vein (RHV) is one of the rarest hepatic vascular anomalies. This anomaly is usually associated with multiple large IRHVs or wider middle hepatic vein (MHV) tributaries. To our knowledge, no clinical studies or case reports related to this RHV anomaly have been published in the English literature except autopsy studies. To our knowledge, a successful LDLT using the RL liver graft without the RHV was performed by our clinic for the first time in the world^[2]. After that, Ray and colleagues reported that they performed successful LDLT using a RL liver graft without a RHV orifice. Herein, we present hepatic venous drainage reconstruction models of RL liver grafts obtained from two LLDs with congenital RHV anomalies.

CASE PRESENTATION

Chief complaint and history of present illness

Case 1: A 25-year-old healthy male (BMI: 20.2 kg/m², total liver volume: 1136 cc, RL: 786 cc, remnant liver: 34%) was admitted to our liver transplant institute to give a part of his liver to his 26-year-old sister with Budd Chiari Syndrome. He had no chronic disease.

Case 2: A 31-year-old healthy male (BMI: 23.7 kg/m², total liver volume: 1428 cc, RL: 1000 cc, remnant liver: 30%) was admitted to our liver transplant institute to give a part of his liver to his 56-year-old uncle with alcoholic liver cirrhosis.

Physical examination

Case 1 and Case 2: Physical examination revealed that vital signs were within normal limits. The LLD candidates were examined according to the donor evaluation algorithm applied in our liver transplant institute.

Laboratory and imaging examinations

Case 1: Biochemical blood tests and viral markers were within normal limits. Contrast-enhanced MDCT showed that the RHV was rudimentary and that the RL was drained by three IRHVs, one of them was located in the hepatocaval ligament. As our institute is experienced in RL drainage models, cadaveric organ donation was insufficient, and the recipient could not provide another potential donor candidate; thus, we decided to accept the LLD candidate.

Case 2: The potential LLD was examined according to the donor evaluation algorithm applied in our institute. Contrast-enhanced MDCT showed congenital absence of the RHV and that the RL was drained by two large IRHVs.

FINAL DIAGNOSIS

Case 1

The healthy individual who had a rudimentary RHV was accepted as a suitable LLD candidate.

Case 2

The healthy individual who had no RHV was accepted as a suitable LLD candidate.

TREATMENT

Case 1

RL hepatectomy was performed as previously described in our institute. Three IRHVs of 5-6 mm diameter, which drained the RL into the IVC, were preserved until the parenchymal transection was completed. Parenchymal transection was performed using the CUSA (Cavtron Ultrasonic Surgical Aspirator, Integra, United States) without Pringles maneuver. During transection, two V5 and one V8 were marked and preserved to be integrated into the venous drainage model. Bloodless RL graft volume and graft-recipient weight ratio were measured as 765 g and 1.03%, respectively.

Case 2

RL hepatectomy was performed as previously described in our institute, all three IRHVs were preserved until the parenchymal transection was completed and transection was performed using the CUSA without Pringles maneuver (**Figure 1**). During transection, two V5 and two V8 were marked and preserved to be integrated into the venous drainage model. Bloodless RL graft volume and graft-recipient weight ratio were measured as 1000 g and 1.02%, respectively. The drainage model was found to be successful by postoperative MDCT. Finally, the recipient was discharged without postoperative complications.

OUTCOME AND FOLLOW-UP

Case 1

The LLD had an uneventful postoperative clinical course. The drainage model was found to be successful by postoperative MDCT. Finally, the recipient was discharged on postoperative day 21 without complications.

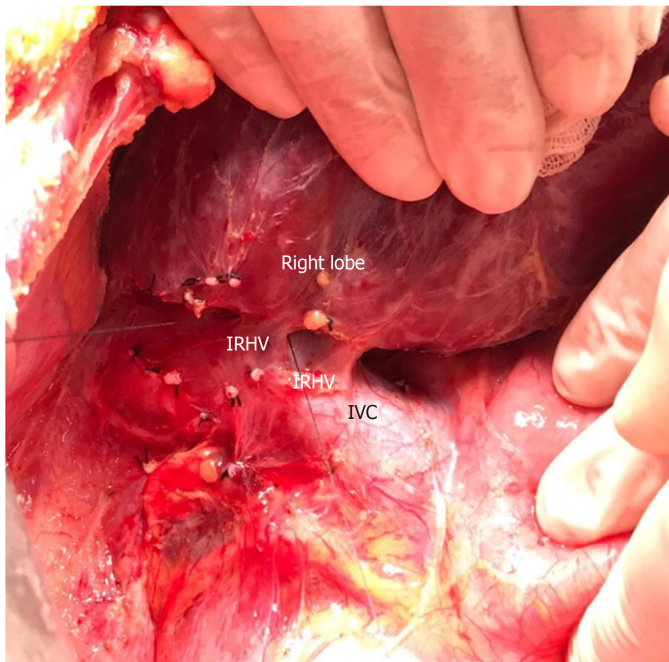


Figure 1 Dissection plan between the right lobe of the liver and inferior vena cava. Intraoperative view of two inferior right hepatic veins draining the right lobe posterior sector. IRHV: Inferior right hepatic vein; IVC: Inferior vena cava.

Case 2

The LLD had an uneventful postoperative clinical course. The drainage model was found to be successful by postoperative MDCT. Finally, the recipient was discharged with minimal biliary complications.

DISCUSSION

Definition of back-table reconstruction techniques for both patients

The perfusion and washing of the liver grafts with preservation solutions on the back-table stage were performed as described previously^[2]. Using the cryopreserved vascular graft materials, a common large opening drainage model was created to include three IRHVs and V8. The rudimentary RHV was also integrated into the drainage model. For this common large opening drainage model, an aortic vascular graft was used as a quilt, while a saphenous vein graft was used to both create a circumferential fence and extend V8 to the main drainage model. Both V5 orifices on the cut surface were first created as a single orifice and then anastomosed directly to the recipient's left hepatic vein stump using an expanded polytetrafluoroethylene vascular graft (Figures 2 and 3). The liver implantation techniques used in both cases were not different from other LT recipients with normal RHV. Postoperative US and MDCT were performed to determine whether the venous drainage model was successful in both recipients (Figure 4).

LDLT has been expanded to overcome the graft shortage and disparity between supply and demand in patients on the LT waiting list. However, unlike a whole size deceased donor liver graft, most of the living liver grafts require reconstruction of the venous structures including RHV, IRHVs and MHV tributaries to restore venous drainage of the corresponding segments to prevent any postoperative congestion. Hepatic venous structures may be delineated using modern imaging techniques: Doppler US, MDCT, and conventional angiography are particularly useful for observing the venous structures. Variations or congenital anomalies in hepatic venous structure in LLD candidates can disqualify the candidate or alter surgical choice. One such hepatic venous anomaly is congenital absence of the RHV or a rudimentary RHV. As vascular anomalies and variations in LLD candidates may cause unexpected complications and difficulties, these vascular anomalies and variations must be evaluated and documented clearly by imaging techniques before surgery. In our cases, the rudimentary or congenitally absent RHV and presence of the IRHVs were identified easily on preoperative MDCT, which allowed us to plan the surgery.

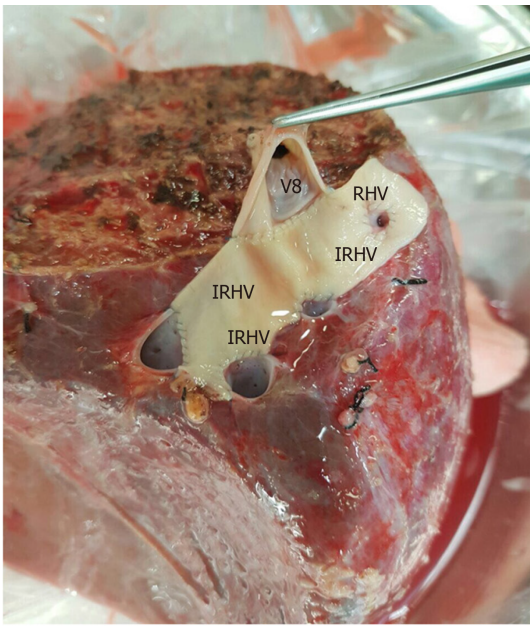


Figure 2 The cryopreserved aortic vascular graft patch was placed between the four orifices as a quilt. After that the segment 8 hepatic vein orifice was extended to the drainage model using a cryopreserved saphenous vein graft. IRHV: Inferior right hepatic vein; V8: 8 vein; RHV: Right hepatic vein.

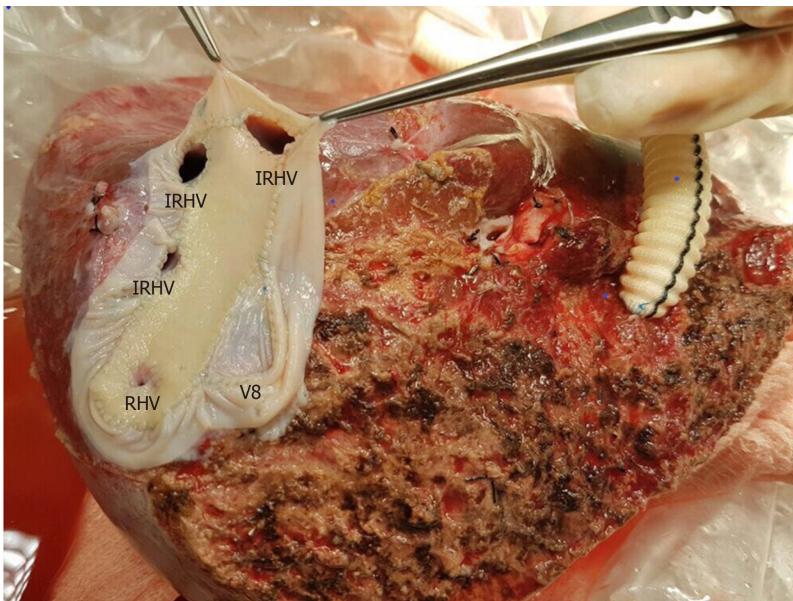


Figure 3 A common large opening drainage model was created using the cryopreserved saphenous vein graft. IRHV: Inferior right hepatic vein; V8: 8 vein; RHV: Right hepatic vein.

Difficulties in hepatic venous drainage in LDLT has been addressed by many studies with many technical considerations and modifications investigated^[1-12]. While controversy exists regarding the ideal criteria and method of incorporating the IRHVs into the graft's drainage system and the ideal method of draining segments 5 and 8, it is agreed that venous congestion due to inadequate outflow reconstruction impairs regeneration, and is associated with increased complications including graft loss^[8,12].

In our patients with absent or rudimentary main RHV and the presence of multiple major IRHVs, a common large opening drainage model allowed for a wider ostium, which achieved faster and easier anastomosis with the IVC reducing the warm ischemia time with an ostium tolerating compression with less risk of compression and obstruction. We reported a similar case from the same center in 2013, but did not find similar reported cases in the English literature^[2]. One case was reported with a liver transplant in the absence of a RHV ostium with the right hepatic vein present and drained into the IVC through a single ostial opening by the middle and left hepatic

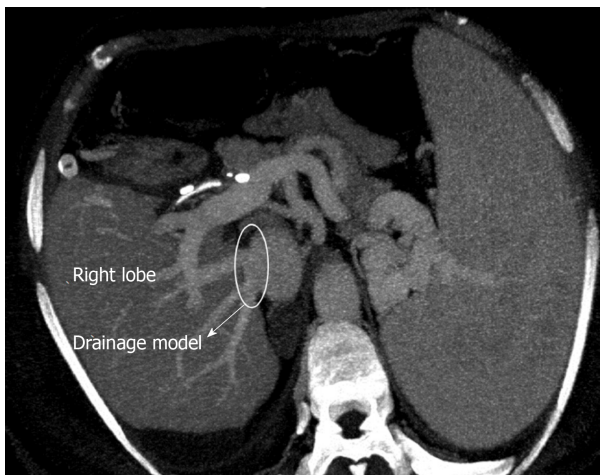


Figure 4 Postoperative contrast axial multidetector computed tomography image shows that the venous drainage model is functional.

veins, in that case a subtotal MHV was to be taken leaving behind the proximal MHV with drainage of the segment 4b and RHV vein into it, as the patient's RHV joined the MHV intra-hepatically^[13].

The venous outflow reconstruction is technically challenging for RL liver grafts with an undrained anterior sector, along with the presence of multiple IRHVs with vulnerability of congestion if not adequately reconstructed. Adding to the complexity is the presence of a wide variability in the pattern of branching of hepatic veins, difficulty in determining the optimal anastomotic site and direction especially in the presence of major IRHVs to anastomose which requires further time^[14,15]. Authors recommend that short hepatic veins with a diameter ≥ 4 mm should be integrated into the drainage system, which is our approach^[2,3,15]. The need for IRHVs to be integrated into the drainage system is even more essential in the absence of adequate drainage through the RHV due to its absence or in cases where it is rudimentary, where in these cases the major IRHVs dominate the venous outflow.

A common large opening reconstruction technique diminishes morbidity as well as potential mortality associated with compromised graft outflow and has been proved to be safe^[1,4-6]. A single, wide orifice is achieved by various venoplasty techniques during back-table procedures using cryopreserved conduits, or the recipient's saphenous vein, or synthetic vascular grafts^[3,5-7]. The technique used to perform a back-table venoplasty to form a single, large orifice remains an easy procedure without added risks^[5]. Also, in the presence of dense adhesions due to previous surgeries, reduced available length of IVC, and multiple collaterals, the outflow reconstruction becomes technically less complex with this technique in addition to reducing the warm ischemia time with one single anastomosis to the IVC.

With regard to the MHV tributaries, which drain the central region of the liver, our approach is to leave the MHV in the donor's side in cases without a segment 4b vein. In cases with a segment 4b vein, the decision to include the MHV in the graft is made with respect to the remnant liver volume. If the remnant liver volume is $\leq 30\%$, the MHV should be left in the donor's side. If the remnant liver volume is $> 30\%$, the decision is made with respect to the diameters of veins draining segment 5 and 8^[2,6].

CONCLUSION

In conclusion, rudimentary or congenital absence of RHV is not an absolute contraindication for RL-LDLT in centers with experience in venous outflow reconstruction and various drainage models. However, it is important to meticulously examine the vascular structures of donor candidates using preoperative radiological instruments.

REFERENCES

- 1 Ara C, Akbulut S, Ince V, Aydin C, Gonultas F, Kayaalp C, Unal B, Yilmaz S. Circumferential Fence With

- the Use of Polyethylene Terephthalate (Dacron) Vascular Graft for All-in-One Hepatic Venous Reconstruction in Right-Lobe Living-Donor Liver Transplantation. *Transplant Proc* 2015; **47**: 1458-1461 [PMID: 26093742 DOI: 10.1016/j.transproceed.2015.04.069]
- 2 **Akbulut S**, Yilmaz M, Eris C, Kutlu R, Yilmaz S. Living-donor liver transplant using the right hepatic lobe without the right hepatic vein: solving the drainage problem. *Exp Clin Transplant* 2013; **11**: 278-282 [PMID: 23767945 DOI: 10.6002/ect.2012.0060]
 - 3 **Hwang S**, Ha TY, Ahn CS, Moon DB, Kim KH, Song GW, Jung DH, Park GC, Namgoong JM, Jung SW, Yoon SY, Sung KB, Ko GY, Cho B, Kim KW, Lee SG. Reconstruction of inferior right hepatic veins in living donor liver transplantation using right liver grafts. *Liver Transpl* 2012; **18**: 238-247 [PMID: 22140053 DOI: 10.1002/lt.22465]
 - 4 **Thorat A**, Jeng LB, Yang HR, Li PC, Li ML, Yeh CC, Chen TH, Hsu SC, Poon KS. Outflow reconstruction for right liver allograft with multiple hepatic veins: "V-plasty" of hepatic veins to form a common outflow channel versus 2 or more hepatic vein-to-inferior vena cava anastomoses in limited retrohepatic space. *Liver Transpl* 2016; **22**: 192-200 [PMID: 26390259 DOI: 10.1002/lt.24342]
 - 5 **Jeng LB**, Thorat A, Li PC, Li ML, Yang HR, Yeh CC, Chen TH, Hsu CH, Hsu SC, Poon KS. "V-Plasty" technique using dual synthetic vascular grafts to reconstruct outflow channel in living donor liver transplantation. *Surgery* 2015; **158**: 1272-1282 [PMID: 25920910 DOI: 10.1016/j.surg.2015.03.018]
 - 6 **Thorat A**, Jeng LB, Li PC, Li ML, Yang HR, Yeh CC, Chen TH, Hsu SC. "Single Oval Ostium Technique" using Polytetrafluoroethylene Graft for Outflow Reconstruction in Right Liver Grafts with venous Anomalies in Living Donor Liver Transplantation. *Hepatogastroenterology* 2015; **62**: 698-702 [PMID: 26897957]
 - 7 **Barut B**, Akbulut S, Kutluturk K, Koc C, Gonultas F, Kayaalp C, Kutlu R, Yilmaz S. Eligibility of Circumferential Fence With the Autologous Peritoneal Patch for Venous Reconstruction in Right Lobe Living-Donor Liver Transplant: A Case Control Study. *Exp Clin Transplant* 2019 [PMID: 31718532 DOI: 10.6002/ect.2018.0325]
 - 8 **Ozbilgin M**, Unek T, Egeli T, Agalar C, Ozkardeşler S, Altay C, Astarcioglu I. Comparison of Patients With and Without Anterior Sector Venous Drainage in Right Lobe Liver Transplantation From Live Donors in Terms of Complications, Rejections, and Graft Survival: Single-Center Experience. *Transplant Proc* 2019; **51**: 1127-1133 [PMID: 31101185 DOI: 10.1016/j.transproceed.2019.01.103]
 - 9 **Sakamoto K**, Ogawa K, Matsui T, Utsunomiya T, Honjo M, Ueno Y, Tamura K, Inoue H, Nakamura T, Watanabe J, Takai A, Tohyama T, Takada Y. Reconstruction of Middle Hepatic Vein Tributaries With Artificial Vascular Grafts in Living Donor Liver Transplant Using Right Lobe Grafts: A Case Series. *Transplant Proc* 2019; **51**: 1506-1510 [PMID: 31010699 DOI: 10.1016/j.transproceed.2019.01.118]
 - 10 **Pravisani R**, Soyama A, Takatsuki M, Hidaka M, Adachi T, Ono S, Hara T, Hamada T, Kanetaka K, Eguchi S. Relationship Between Venous Drainage Patterns and Regeneration of Segments 5 and 8 in Right Lobe Grafts in Adult Living-Donor Liver Transplant Recipients. *Exp Clin Transplant* 2019; **17**: 529-535 [PMID: 30995896 DOI: 10.6002/ect.2018.0155]
 - 11 **Ali MA**, Yong CC, Eng HL, Wang CC, Lin TL, Li WF, Wang SH, Lin CC, Yap A, Chen CL. Cryopreserved arterial grafts as a conduit in outflow reconstruction in living donor liver transplantation. *J Hepatobiliary Pancreat Sci* 2015; **22**: 498-504 [PMID: 25783415 DOI: 10.1002/jhbp.240]
 - 12 **Pravisani R**, Soyama A, Takatsuki M, Hidaka M, Adachi T, Ono S, Hara T, Hamada T, Eguchi S. Impact of the Inferior Right Hepatic Veins on Right Liver Lobe Regeneration in Living-Donor Liver Transplant: 3-Dimensional Computed Tomography Scan Analyses in Donors and Recipients. *Exp Clin Transplant* 2019; **17**: 768-774 [PMID: 30968763 DOI: 10.6002/ect.2018.0254]
 - 13 **Ray S**, Anila T, Jha SK, Rawat S, Rawat KS, Singhvi SK. Is the absence of Right Hepatic Vein opening into Inferior Vena Cava a contraindication for right lobe liver donation in Living Donor Liver Transplantation? Common hepatic venous trunk-A rare hepatic vein anomaly: A case report and review. *Int J Surg Case Rep* 2017; **30**: 159-161 [PMID: 28012335 DOI: 10.1016/j.ijser.2016.10.039]
 - 14 **Shilal P**, Tuli A. Anatomical variations in the pattern of the right hepatic veins draining the posterior segment of the right lobe of the liver. *J Clin Diagn Res* 2015; **9**: AC08-AC12 [PMID: 25954610 DOI: 10.7860/JCDR/2015/8736.5671]
 - 15 **Hwang S**, Lee SG, Park KM, Kim KH, Ahn CS, Moon DB, Ha TY. Quilt venoplasty using recipient saphenous vein graft for reconstruction of multiple short hepatic veins in right liver grafts. *Liver Transpl* 2005; **11**: 104-107 [PMID: 15690544 DOI: 10.1002/lt.20314]



Published by **Baishideng Publishing Group Inc**
7041 Koll Center Parkway, Suite 160, Pleasanton, CA 94566, USA

Telephone: +1-925-3991568

E-mail: bpgoffice@wjgnet.com

Help Desk: <https://www.f6publishing.com/helpdesk>

<https://www.wjgnet.com>

