

# World Journal of *Gastrointestinal Surgery*

*World J Gastrointest Surg* 2021 January 27; 13(1): 1-95



**OPINION REVIEW**

- 1 Colonic Crohn's disease – decision is more important than incision: A surgical dilemma  
*Chiarello MM, Cariati M, Brisinda G*

**MINIREVIEWS**

- 7 Role of artificial intelligence in hepatobiliary and pancreatic surgery  
*Bari H, Wadhvani S, Dasari BVM*

**ORIGINAL ARTICLE****Retrospective Cohort Study**

- 19 Laparoscopic hepatectomy reduces postoperative complications and hospital stay in overweight and obese patients  
*Heise D, Bednarsch J, Kroh A, Schipper S, Eickhoff R, Coolsen M, Van Dam R, Lang S, Neumann U, Ulmer F*

**Retrospective Study**

- 30 Pancreas-preserving duodenal resections *vs* pancreatoduodenectomy for groove pancreatitis. Should we revisit treatment algorithm for groove pancreatitis?  
*Egorov V, Petrov R, Schegolev A, Dubova E, Vankovich A, Kondratyev E, Dobriakov A, Kalinin D, Schvetz N, Poputchikova E*
- 50 Evaluation of prognostic factors and clinicopathological patterns of recurrence after curative surgery for colorectal cancer  
*Melli F, Bartolini I, Risaliti M, Tucci R, Ringressi MN, Muiesan P, Taddei A, Amedei A*

**SYSTEMATIC REVIEWS**

- 76 Xanthogranulomatous appendicitis: A comprehensive literature review  
*Akbulut S, Demyati K, Koc C, Tuncer A, Sahin E, Ozcan M, Samdanci E*

**CASE REPORT**

- 87 Multidetector computed tomography three-dimensional and multiplanar reconstruction diagnosis of a rare cause of gastrointestinal bleeding: A case report  
*Cai Y, Chen XB, Mai DH, Wu P, Chen YH, Chen H*

**ABOUT COVER**

Editorial board member of *World Journal of Gastrointestinal Surgery*, Dr. Raphael LC Araujo is a Professor of Liver Surgery at Federal University of São Paulo (UNIFESP -Brazil). After earning his medical degree from University of the State of Rio de Janeiro (2003), he undertook training in Surgical Oncology at AC Camargo Cancer Center. Afterwards, he spent two years (2010-2012) as Research Fellow in Hepatopancreatobiliary Service at Memorial Sloan-Kettering Cancer Center (New York, United States), working on multimodal approaches for hepatopancreatobiliary malignancies, mainly for colorectal liver metastases and pancreas cancer. Subsequently, he performed residency in Hepatopancreatobiliary Service at Hospital Paul Brousse (France; 2012-2013) and then earned both a PhD (2015) and post-doctorate (2017) degree in Gastroenterology from the University of São Paulo. (L-Editor: Filipodia)

**AIMS AND SCOPE**

The primary aim of *World Journal of Gastrointestinal Surgery* (*WJGS, World J Gastrointest Surg*) is to provide scholars and readers from various fields of gastrointestinal surgery with a platform to publish high-quality basic and clinical research articles and communicate their research findings online.

*WJGS* mainly publishes articles reporting research results and findings obtained in the field of gastrointestinal surgery and covering a wide range of topics including biliary tract surgical procedures, biliopancreatic diversion, colectomy, esophagectomy, esophagostomy, pancreas transplantation, and pancreatectomy, etc.

**INDEXING/ABSTRACTING**

The *WJGS* is now abstracted and indexed in Science Citation Index Expanded (SCIE, also known as SciSearch®), Current Contents/Clinical Medicine, Journal Citation Reports/Science Edition, PubMed, and PubMed Central. The 2020 edition of Journal Citation Reports® cites the 2019 impact factor (IF) for *WJGS* as 1.863; IF without journal self cites: 1.824; Ranking: 109 among 210 journals in surgery; Quartile category: Q3; Ranking: 77 among 88 journals in gastroenterology and hepatology; and Quartile category: Q4.

**RESPONSIBLE EDITORS FOR THIS ISSUE**

Production Editor: Jia-Hui Li; Production Department Director: Xiang Li; Editorial Office Director: Ya-Juan Ma.

**NAME OF JOURNAL**

*World Journal of Gastrointestinal Surgery*

**ISSN**

ISSN 1948-9366 (online)

**LAUNCH DATE**

November 30, 2009

**FREQUENCY**

Monthly

**EDITORS-IN-CHIEF**

Shu-You Peng, Varut Lohsirirawat, Jin Gu

**EDITORIAL BOARD MEMBERS**

<https://www.wjgnet.com/1948-9366/editorialboard.htm>

**PUBLICATION DATE**

January 27, 2021

**COPYRIGHT**

© 2021 Baishideng Publishing Group Inc

**INSTRUCTIONS TO AUTHORS**

<https://www.wjgnet.com/bpg/gerinfo/204>

**GUIDELINES FOR ETHICS DOCUMENTS**

<https://www.wjgnet.com/bpg/GerInfo/287>

**GUIDELINES FOR NON-NATIVE SPEAKERS OF ENGLISH**

<https://www.wjgnet.com/bpg/gerinfo/240>

**PUBLICATION ETHICS**

<https://www.wjgnet.com/bpg/GerInfo/288>

**PUBLICATION MISCONDUCT**

<https://www.wjgnet.com/bpg/gerinfo/208>

**ARTICLE PROCESSING CHARGE**

<https://www.wjgnet.com/bpg/gerinfo/242>

**STEPS FOR SUBMITTING MANUSCRIPTS**

<https://www.wjgnet.com/bpg/GerInfo/239>

**ONLINE SUBMISSION**

<https://www.f6publishing.com>





## Xanthogranulomatous appendicitis: A comprehensive literature review

Sami Akbulut, Khaled Demyati, Cemalettin Koc, Adem Tuncer, Emrah Sahin, Mehmet Ozcan, Emine Samdanci

**ORCID number:** Sami Akbulut 0000-0002-6864-7711; Khaled Demyati 0000-0002-9591-2664; Cemalettin Koc 0000-0002-5676-6772; Adem Tuncer 0000-0001-5381-513X; Emrah Sahin 0000-0001-5267-9068; Mehmet Ozcan 0000-0003-0969-1373; Emine Samdanci 0000-0002-0034-5186.

**Author contributions:** Akbulut S, Koc C and Demyati K designed the report; Tuncer A, Sahin E and Akbulut S performed the literature review; Ozcan M and Samdanci E provided the histopathological information; all authors reviewed the final version.

**Conflict-of-interest statement:** The authors declare no competing interests.

**PRISMA 2009 Checklist statement:** The authors have read the PRISMA 2009 Checklist, and the manuscript was prepared and revised according to the PRISMA 2009 Checklist.

**Open-Access:** This article is an open-access article that was selected by an in-house editor and fully peer-reviewed by external reviewers. It is distributed in accordance with the Creative Commons Attribution NonCommercial (CC BY-NC 4.0) license, which permits others to distribute, remix, adapt, build

**Sami Akbulut, Khaled Demyati, Cemalettin Koc, Adem Tuncer, Emrah Sahin,** Department of Surgery and Liver Transplant Institute, Inonu University Faculty of Medicine, Malatya 44280, Turkey

**Khaled Demyati,** Department of Surgery, An-Najah National University, Nablus, 44839, Palestine

**Mehmet Ozcan, Emine Samdanci,** Department of Pathology, Inonu University Faculty of Medicine, Malatya 44280, Turkey

**Corresponding author:** Sami Akbulut, MD, Professor, Department of Surgery and Liver Transplant Institute, Inonu University Faculty of Medicine, Elazig Yolu 10. Km, Malatya 44280, Turkey. [akbulutsami@gmail.com](mailto:akbulutsami@gmail.com)

### Abstract

#### BACKGROUND

Xanthogranulomatous inflammation is characterized histologically by a collection of lipid-laden macrophages admixed with lymphocytes, plasma cells, neutrophils, and often multinucleated giant cells with or without cholesterol clefts.

#### AIM

To review the medical literature on xanthogranulomatous appendicitis (XGA).

#### METHODS

We present a patient with XGA and review published articles on XGA accessed via the PubMed, MEDLINE, Google Scholar, and Google databases. Keywords used were "appendix vermiformis," "appendectomy," "acute appendicitis," and "XGA." The search included articles published before May 2020, and the publication language was not restricted. The search included letters to the editor, case reports, review articles, original articles, and meeting presentations. Articles or abstracts containing adequate information about age, sex, clinical presentation, white blood cells, initial diagnosis, surgical approach, histopathological and immunohistochemical features of appendectomy specimens were included in the study.

#### RESULTS

A total of 29 articles involving 38 patients with XGA, were retrospectively analyzed. Twenty (52.6%) of the 38 patients, aged 3 to 78 years (median: 34; IQR:

upon this work non-commercially, and license their derivative works on different terms, provided the original work is properly cited and the use is non-commercial. See: <http://creativecommons.org/licenses/by-nc/4.0/>

**Manuscript source:** Unsolicited manuscript

**Specialty type:** Gastroenterology and hepatology

**Country/Territory of origin:** Turkey

**Peer-review report's scientific quality classification**

Grade A (Excellent): 0

Grade B (Very good): B, B

Grade C (Good): 0

Grade D (Fair): 0

Grade E (Poor): 0

**Received:** October 11, 2020

**Peer-review started:** October 11, 2020

**First decision:** November 3, 2020

**Revised:** November 12, 2020

**Accepted:** December 1, 2020

**Article in press:** December 1, 2020

**Published online:** January 27, 2021

**P-Reviewer:** Aranda-Narvaez J

**S-Editor:** Fan JR

**L-Editor:** Webster JR

**P-Editor:** Li JH



31) were female, and the remaining 18 (47.4%) were male. Twenty-five patients were diagnosed with acute appendicitis, ruptured appendicitis, or subacute appendicitis, and the remaining 13 patients underwent surgery for tumoral lesions of the ileocecal region. Twenty-two of the patients underwent urgent or semi-urgent surgery, and the remaining 16 patients underwent interval appendectomy.

## CONCLUSION

Xanthogranulomatous inflammation rarely affects the appendix vermiformis. It is associated with significant diagnostic and therapeutic dilemmas due to its variable presentation. It is often associated with interval appendectomies, and a significant number of patients require bowel resection due to the common presentation of a tumoral lesion. XGA is usually identified retrospectively on surgical pathology and has no unique features in preoperative diagnostic studies.

**Key Words:** Appendix vermiformis; Acute appendicitis; Appendectomy; Interval appendectomy; Xanthogranulomatous inflammation; CD68 antibody staining

©The Author(s) 2021. Published by Baishideng Publishing Group Inc. All rights reserved.

**Core Tip:** Xanthogranulomatous inflammation is characterized histologically by a collection of lipid-laden macrophages admixed with lymphocytes, plasma cells, neutrophils, and often multinucleated giant cells with or without cholesterol clefts. Xanthogranulomatous appendicitis (XGA) has rarely been reported to date. In this review article, we present a patient with XGA, and review data from all articles published on this rare situation. This review study shows that XGA is associated with significant diagnostic and therapeutic dilemmas due to its variable presentation. It is often associated with interval appendectomies, and a significant number of patients require bowel resection due to the common presentation of a tumoral lesion.

**Citation:** Akbulut S, Demyati K, Koc C, Tuncer A, Sahin E, Ozcan M, Samdanci E. Xanthogranulomatous appendicitis: A comprehensive literature review. *World J Gastrointest Surg* 2021; 13(1): 76-86

**URL:** <https://www.wjgnet.com/1948-9366/full/v13/i1/76.htm>

**DOI:** <https://dx.doi.org/10.4240/wjgs.v13.i1.76>

## INTRODUCTION

Xanthogranulomatous inflammation is a well-known form of inflammation, characterized histologically by a collection of lipid-laden macrophages admixed with lymphocytes, plasma cells, neutrophils, and often multinucleated giant cells with or without cholesterol clefts<sup>[1]</sup>. Xanthogranulomatous inflammation was first described in the urogenital system by Osterlind in 1944<sup>[2]</sup>. Since then, it has been reported in other organs, such as the gallbladder, stomach, colon, anorectal area, endometrium, ovary, epididymis, vagina, testis, prostate, skin, urinary bladder, bone, thyroid, lung and adrenal glands, fallopian tubes, and the appendix vermiformis<sup>[3-9]</sup>.

Xanthogranulomatous appendicitis (XGA) is rarely reported in the appendix vermiformis. Some studies stated that the first XGA case was reported by Cozzuto and colleagues<sup>[1,3]</sup>. Other studies stated that Birch and colleagues<sup>[4,10-13]</sup> were the first to report this entity. However, according to our literature search, the first case of XGA was described by Dymock and colleagues in 1977<sup>[14]</sup>. Its clinical significance includes the significant diagnostic challenge it causes because it can mimic clinically, radiologically, and even pathologically malignant tumors as well as other inflammatory processes of the appendix vermiformis. It is usually found retrospectively on surgical pathology and has no unique features on imaging studies, including abdominopelvic computed tomography. Little information has been written in the literature regarding this entity. Moreover, its clinical implications remain to be evaluated. In this review article, we present a case of XGA, and review data from all articles published on XGA.

## MATERIALS AND METHODS

The primary aim of this study was to review the articles published in the medical literature on XGA. To achieve this objective, a literature search was conducted on PubMed, MEDLINE, Google Scholar, and Google databases using the following keywords: "Appendix vermiformis," "acute appendicitis," "XGA," "interval appendectomy," and "appendectomy." All documents published on XGA before May 2020 were reviewed. The corresponding authors of the articles with substantially large amounts of missing information were e-mailed to obtain information on their cases. As a result, articles without an accessible full-text version, those that did not provide adequate information in their abstracts, and those that did not include comprehensive information as that provided in other studies were excluded. As some enrolled articles were published in the form of a literature review, their tables were also used. The following information was collected: Reference list, publication year, paper type (full text, abstract, poster), age, sex, clinical presentation, white blood cell (WBC) count, radiological tools, surgical approach, histopathological features (giant cells, plasma cells, foamy histiocytes, CD68 stain), and follow-up. The secondary aim of this study was to present a 66-year-old woman with XGA.

## RESULTS

### *Review of the literature*

Although a total of 36 article titles<sup>[3-38]</sup> matched as a result of the literature review conducted in accordance with the criteria specified in the methodology section, seven articles<sup>[1,14,33-37]</sup> were excluded from the study due to the absence of demographic and clinical data of the patients. A total of 38 patients, 20 (52.6%) female and 18 (47.4%) male, aged from 3 to 78 years (median: 34; IQR: 31) were included in this study. Fifteen patients' WBC values were reported, and 13 (86.7%) of them had leukocytosis. Treatment was planned for 25 patients with a pre-diagnosis of acute appendicitis, ruptured appendicitis, or subacute appendicitis. On the other hand, treatment was planned for nine patients due to a mass in the ileocecal region. After appropriate medical treatment for a total of 16 patients, interval appendectomy was performed. Of the 29 articles, 27 were published in English, one in Japanese, and one in Spanish. The full text was obtained for 28 of the 29 articles, whereas only the abstract was available for one paper. The details of the demographic and clinical characteristics of the patients are given in Tables 1 and 2.

### *Case presentation*

A 66-year-old female patient was admitted to our emergency unit because of right lower quadrant pain, which started 3 d prior to admission. She had a medical history of left hemiparesis secondary to cerebrovascular events, mitral valve stenosis, and atrial fibrillation. As the patient had a speech disorder, the history was taken from her husband and children who lived in the same house. Physical examination revealed significant rebound tenderness in the right lower quadrant. Biochemical analyses were as follows: WBC count 12.900/mL (4.300-10.300), platelets 337000/mL (156000-373000), neutrophils 80.7%, CRP 13.7 mg/dL (0-0.35), and international normalized ratio 1.7 (0.8-1.2). Ultrasonography revealed an edematous and aperistaltic tubular structure with a diameter of 2 cm in the right lower quadrant of the abdomen that was not compressible with external pressure. In addition, free fluid was detected around the defined structure, suggesting ruptured appendicitis. After evaluating the clinical, radiological, and biochemical blood parameters of the patient, she was diagnosed with ruptured appendicitis, and underwent surgery under emergency conditions. In view of the logistic problems with laparoscopic equipment at the time of surgery, laparotomy was performed using an infraumbilical midline incision. The exploration showed that the ileocecal region was completely surrounded by the omentum, and the sigmoid colon was attached to this defined area. After careful dissection of the omentum and sigmoid colon, a ruptured appendix with distal necrosis was observed, and the surrounding pus was then aspirated. As the stump of the appendix was very large and inflamed, appendectomy was performed after a clamp was placed at the junction with the cecum. The stump was closed with 3/0 polypropylene sutures using the transfixion suture technique. One drain was placed in the pelvis, and the operation was terminated. The pathology report was prepared as ruptured appendicitis secondary to xanthogranulomatous inflammation (Figures 1-3). Antibiotic treatment consisting of ceftriaxone and metronidazole was administered for 5 d postoperatively.

**Table 1 Summary of 29 articles involving 38 patients with xanthogranulomatous appendicitis published in the medical literature between 1992 and 2019**

No.	Ref.	Year	Country	Language	Article type	Article type	Age	Sex	Clinical presentation	WBC
1	Quadri <i>et al</i> <sup>[15]</sup>	2019	United States	English	Case series	Full text	64	M	RLQ pain + palpable mass	NA
2	Yang <i>et al</i> <sup>[16]</sup>	2018	South Korea	English	Congress present	Full text	69	M	NA	NA
3	Al-Zaidi <i>et al</i> <sup>[36]</sup>	2018	India	English	Case report	Full text	48	M	RLQ pain	16000
4	Adhikari <i>et al</i> <sup>[4]</sup>	2019	India	English	Case report	Full text	49	F	RLQ pain + fever	12200
5	Kaushik <i>et al</i> <sup>[17]</sup>	2017	India	English	Case report	Full text	47	F	Abdominal pain, vomiting, fever	14000
6	Hoabam <i>et al</i> <sup>[10]</sup>	2017	India	English	Case report	Full text	56	F	RLQ pain	14000
7	Mehrotra <i>et al</i> <sup>[18]</sup>	2017	India	English	Case report	Full text	30	F	RLQ pain	Normal
8	Laiphrakpam <i>et al</i> <sup>[19]</sup>	2017	India	English	Case report	Full text	36	M	RLQ Pain	Normal
9	Nam <i>et al</i> <sup>[20]</sup>	2016	South Korea	English	Case report	Full text	23	F	Low abdominal pain	NA
10	Cavusoglu <i>et al</i> <sup>[21]</sup>	2016	Turkey	English	Case report	Full text	12	M	NA	NA
							11	M	NA	NA
11	Jusoh <i>et al</i> <sup>[5]</sup>	2016	Malaysia	English	Case report	Full text	16	M	RLQ pain	NA
12	Thapa <i>et al</i> <sup>[6]</sup>	2016	Nepal	English	Case report	Full text	19	F	RLQ pain	NA
13	Singh <i>et al</i> <sup>[7]</sup>	2015	India	English	Case report	Full text	21	F	RLQ pain	NA
14	Altay <i>et al</i> <sup>[22]</sup>	2015	Turkey	English	Case report	Full text	73	F	RLQ pain	Leukocytosis
15	Chandanwale <i>et al</i> <sup>[11]</sup>	2015	India	English	Case report	Full text	40	F	RLQ pain	NA
16	Montazer <i>et al</i> <sup>[23]</sup>	2014	Iran	English	Case report	Full text	29	F	RLQ pain	13000
17	Kochhar <i>et al</i> <sup>[24]</sup>	2014	India	English	Case report	Full text	50	M	RLQ pain + fever	24000
18	Al-Rawabdeh <i>et al</i> <sup>[12]</sup>	2013	United States	English	Case report	Full text	11	M	RLQ pain	4900
19	Mado <i>et al</i> <sup>[25]</sup>	2013	Japan	English	Image in surgery	Full text	78	M	RLQ pain	NA
20	Martinez-Garza <i>et al</i> <sup>[26]</sup>	2011	Spain	Spanish	Case report	Full text	30	F	RLQ pain	13700
21	Omer <i>et al</i> <sup>[8]</sup>	2011	Sudan	English	Case report	Full text	49	M	RLQ pain	NA
22	Omori <i>et al</i> <sup>[27]</sup>	2011	Japan	Japanese	Case report	Full text	57	F	RLQ pain	NA
23	Young <i>et al</i> <sup>[28]</sup>	2009	United States	English	Case report	Full text	32	F	RLQ pain	22000
24	Chuang <i>et al</i> <sup>[29]</sup>	2005	Taiwan	English	Case report	Abstract	39	M	RLQ pain	NA
25	Guo <i>et al</i> <sup>[30]</sup>	2003	United States	English	Original article	Full text	4	F	NA	NA
							12	M	NA	NA
							13	M	NA	NA
							3	M	NA	NA
							9	M	NA	NA
							29	F	NA	NA
							29	F	NA	NA
							27	M	NA	NA
26	Munichor <i>et al</i> <sup>[3]</sup>	2000	Israel	English	Case report	Full text	37	F	RLQ pain	12000
27	McVey <i>et al</i> <sup>[32]</sup>	1994	United States	English	Letter	Full text	40	F	RLQ pain	12100

28	Birch <i>et al</i> <sup>[13]</sup>	1993	United Kingdom	English	Brief report	Full text	51	M	Perineal pain	NA
							66	F	Right flank pain	20000
29	Rogers <i>et al</i> <sup>[9]</sup>	1992	United Kingdom	English	Case report	Full text	56	F	RLQ pain	NA

WBC: White blood cell; RLQ: Right lower quadrant.

The patient was discharged without any postoperative complications.

## DISCUSSION

Acute appendicitis is the most common acute surgical condition of the abdomen. Most of the resected appendectomy specimens have been reported to have marked cellular infiltration, predominantly by neutrophils. In contrast, the occurrence of xanthogranulomatous inflammation is extremely rare. In a 2-year study that was performed to determine the incidence of various non-neoplastic and neoplastic lesions of the appendix, only one case of this entity was identified (0.22%)<sup>[34]</sup>. Similarly, Laishram and colleagues<sup>[37]</sup> reported that the incidence of XGA was 0.25% in 4298 appendectomy specimens. On the other hand, Shaik and colleagues<sup>[35]</sup> stated that the incidence of XGA among patients who underwent appendectomy was 0.64%.

Grossly, the typical findings are bright yellow or golden yellow mass-like lesions associated with abscess cavities<sup>[1,36]</sup>. Kaushik and colleagues<sup>[17]</sup> studied the cytological evaluation of the touch imprint preparation for intraoperative diagnosis of XGA. The smears revealed benign glandular epithelial cell groups and sheets of xanthoma cells along with multinucleate histiocytic giant cells in the background of neutrophils and mononuclear inflammatory cells. Microscopic examination of XGA usually reveals a nodular or diffuse mucosal to transmural collection of macrophages, including foamy histiocytes (xanthoma-type cells), intermixed with varying amounts of other inflammatory cells<sup>[7]</sup>.

Although the histopathological features of the xanthogranulomatous process have been defined, the exact etiopathogenesis of XGA is still unknown. Proposed theories include defective lipid transport, immunologic disturbances of leukocyte and macrophage chemotaxis, infection by lowvirulence organisms, such as *Proteus* and *Escherichia* species, and lymphatic obstruction<sup>[7,13,17,25,31,34]</sup>.

Cozzutto and colleagues<sup>[1]</sup> performed an extensive review of all cases from various organs. In that study, the authors noted that the xanthogranulomatous process is usually associated with inflammation, hemorrhage, and necrosis. They suggested that hemorrhage may play a major role in the development of foamy macrophages, postulating that the ingested erythrocytes and platelets at the bleeding site overwhelm the lysosomal system of the macrophages, causing deposition of phospholipids, which results in a foamy appearance of the macrophages. Other authors have suggested that there are several factors that may precipitate XGA, including lumen obstruction, suppurative inflammation, hemorrhage, and local tissue hypoxia, with no single pathophysiological factor that can possibly cause XGA<sup>[5,30,37]</sup>.

Other lesions with granulomatous inflammation and foam cells can be seen in the differential diagnoses, such as Crohn's disease and malakoplakia. The absence of transmural involvement by granulomas can exclude Crohn's disease, and the absence of Michaelis Gutmann bodies can rule out malakoplakia. Furthermore, it can be very challenging to differentiate XGA from an infiltrative cancer because XGA might present as a mass lesion with extension of fibrosis and inflammation to the surrounding tissues, mimicking an infiltrative cancer<sup>[4,7,11,24,30,36]</sup>.

Most XGA cases reported were in the adult age group, with the median age of presentation in this review being 34 years. The mean age (35.9 years) identified in this review was lower than the previously reported mean age of 47.9 years (83%, 21-78 years)<sup>[36]</sup>. This appears to be caused by the recent, more XGA pediatric reports published. However, this disease remains more common in adults, with only 6 out of 38 patients in this review belonging to the pediatric age group (15.8%). The oldest patient diagnosed with XGA in this review was 78 years old, who presented with a mucocele of the appendix<sup>[25]</sup>, and the youngest affected patient was 3 years old, diagnosed with interval appendectomy<sup>[30]</sup>. No sex predilection was reported for XGA<sup>[34,36]</sup>, and in this review, there was no significant difference in the number of cases reported between females (52.6%) and males (47.4%).



**Table 2** Introduction to 29 articles published in the medical literature from 1992 to 2019 involving 38 xanthogranulomatous appendicitis patients

No.	Preoperative Diagnosis	Surgical approach	Giant Cells	Plasma Cells	Eosinophils	CD68 Stain	Foamy Histiocytes
1	Mass	Right hemicolectomy	NA	NA	NA	NA	NA
2	Perforated App	Appendectomy (Interval)	NA	NA	NA	NA	NA
3	Perforated App	Right hemicolectomy	Yes	Yes	NA	Yes	Yes
4	AAp	Appendectomy	Yes	Yes	Yes	NA	Yes
5	Neoplastic mass	Limited colon resection	Yes	Yes	Yes	NA	Yes
6	AAp	Appendectomy	Yes	Yes	NA	NA	Yes
7	AAp	Appendectomy	Yes	NA	NA	NA	Yes
8	AAp	Appendectomy	Yes	Yes	NA	NA	Yes
9	Chronic Ap or mucocele	Appendectomy	NA	NA	NA	Yes	Yes
10	Mass	Appendectomy (Interval)	Yes	Yes	NA	Yes	NA
	AAp	Appendectomy (Interval)	Yes	Yes	NA	NA	NA
11	AAp	Appendectomy (Interval)	Yes	NA	NA	NA	Yes
12	AAp	Appendectomy (Interval)	Yes	Yes	Yes	NA	Yes
13	AAp	Appendectomy	Yes	Yes	Yes	Yes	Yes
14	Mass	Appendectomy	NA	NA	NA	Yes	NA
15	Mass	Right hemicolectomy	Yes	Yes	NA	NA	Yes
16	AAp	Appendectomy	Yes	NA	NA	Yes	Yes
17	AAp	Right hemicolectomy + ileostomy	Yes	Yes	NA	NA	Yes
18	AAp	Appendectomy	Yes	Yes	NA	NA	NA
19	Mucocele	Ileocecal resection	NA	NA	NA	NA	Yes
20	AAp	Appendectomy	NA	NA	NA	NA	Yes
21	Mass	Appendectomy (Interval)	Yes	Yes	NA	NA	NA
22	Mass	Right hemicolectomy + right nephrectomy + oophorectomy	NA	Yes	NA	NA	Yes
23	AAp	Appendectomy (Interval)	NA	NA	NA	NA	NA
24	Colitis of cecum	Right hemicolectomy	NA	NA	Yes	NA	NA
25	AAp	Appendectomy (Interval)	Yes	NA	NA	NA	NA
	AAp	Appendectomy (Interval)	No	NA	NA	NA	NA
	AAp	Appendectomy (Interval)	No	NA	NA	NA	NA
	AAp	Appendectomy (Interval)	No	NA	NA	NA	NA
	AAp	Appendectomy (Interval)	Yes	NA	NA	NA	NA
	AAp	Appendectomy (Interval)	No	NA	NA	NA	NA
	Subacute AAp.	Appendectomy (Interval)	No	NA	NA	NA	NA
	Subacute AAp.	Appendectomy (Interval)	Yes	NA	NA	NA	NA
26	AAp	Appendectomy	NA	Yes	Yes	Yes	Yes
27	Mass	Appendectomy (Interval)	NA	Yes	NA	NA	Yes
28	AAp	Appendectomy	NA	Yes	NA	NA	Yes
	Mass	Appendectomy	NA	Yes	NA	NA	Yes
29	Fistula	Appendectomy	NA	NA	NA	NA	NA

Patients with XGA usually present with right lower abdominal quadrant pain, fever, nausea, and vomiting. However, the clinical presentation of XGA is variable, which seems to vary with the spread of the disease. While some authors suggested an association of the xanthogranulomatous response with long-standing inflammation of the appendix and formation of the appendiceal mass<sup>[34]</sup>, others have reported cases of XGA with typical signs and symptoms of acute appendicitis<sup>[31]</sup>. In this review, 22 of the 38 reported cases were diagnosed with acute appendicitis (57.9%), two of which were found to be ruptured.

XGA showed a higher incidence in interval appendectomies<sup>[6,16,20]</sup>. Guo *et al*<sup>[30]</sup> reviewed the histopathology of all interval appendectomy specimens within a four-year period, and compared them with a control group of patients who had acute appendicitis and underwent routine acute appendectomy. The study revealed that xanthogranulomatous inflammation is common in interval appendectomy specimens. They represented 36% of the interval appendectomy cases in their series, but they did not occur in the emergency appendectomy group.

Due to the destructive nature of the disease, XGA can occasionally present with a mass lesion that can mimic locally advanced cancer, but it has a benign course and can be cured surgically. Altay and colleagues reported uterine and right adrenal involvement, presenting as a complicated pelvic abscess on radiological imaging<sup>[22]</sup>. In this review, 13 of the 38 patients had a mass (34%), and two patients had a mucocele. Eight patients required bowel resection ranging from limited ileocecal resection to formal right hemicolectomy. Of the 38 patients, 30 underwent appendectomy, 16 of which as an interval appendectomy.

The variable presentation of XGA requires the consideration of acute appendicitis, a mucinous epithelial neoplasm, a non-mucinous epithelial neoplasm, and a range of chronic infectious diseases. Atypical appendiceal pathologies ranging from neoplasms to inflammatory conditions can mimic and even cause a superimposed acute appendicitis, making them difficult to differentiate from typical inflammation. Contrast-enhanced multidetector computed tomography is the gold standard and the most cost-effective diagnostic test for appendicitis in non-pregnant adults with right lower quadrant pain<sup>[15,38,39]</sup>. However, radiological findings are non-specific, and XGA is usually found retrospectively on surgical pathology and has no unique features on abdominopelvic contrast-enhanced computed tomography<sup>[15]</sup>.

---

## CONCLUSION

---

In summary, xanthogranulomatous inflammation is an unusual, destructive, chronic inflammatory process that involves various organs. While it rarely affects the appendix vermiformis, it is associated with significant diagnostic and therapeutic dilemmas due to its variable presentation. It is more often associated with interval appendectomies, and a significant number of patients require bowel resection due to the common presentation of a mass lesion. XGA is usually identified retrospectively on pathological examination of the appendiceal specimen, and has no unique features on imaging studies including contrast-enhanced computed tomography.

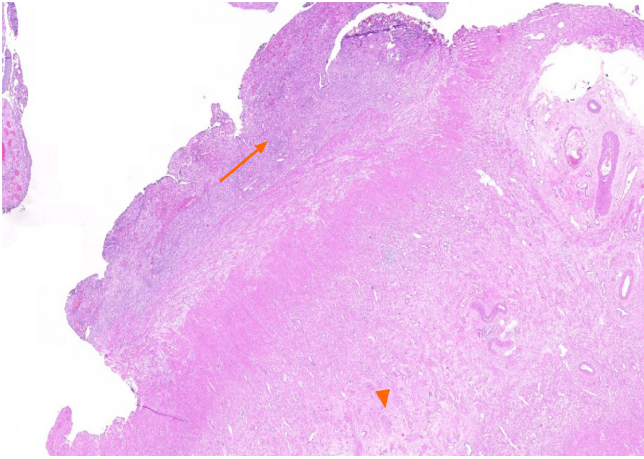


Figure 1 Fibrous obliteration of appendix vermiformis (arrow head), acute and chronic inflammatory cell infiltration (arrow) within the appendix wall and subserosal fatty tissue (HE × 10).

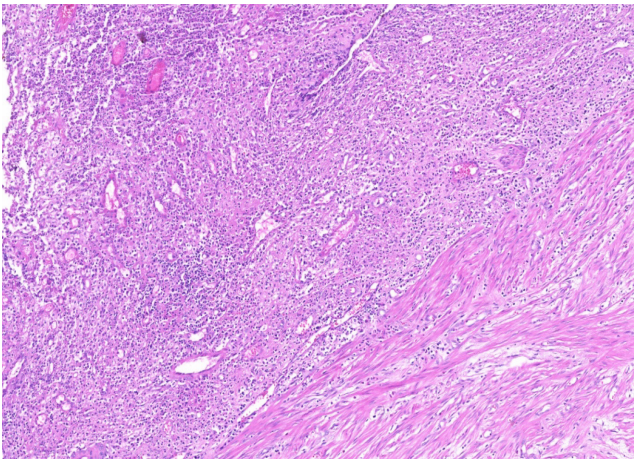


Figure 2 Xanthogranulomatous inflammation (a mixture of macrophages, lymphocytes, plasma cells, and neutrophils) (HE × 50).




Figure 3 Macrophages showing positive staining for CD68 antibody.

## ARTICLE HIGHLIGHTS

**Research background**

Xanthogranulomatous inflammation is characterized histologically by a collection of lipid-laden macrophages admixed with lymphocytes, plasma cells, neutrophils, and often multinucleated giant cells with or without cholesterol clefts

**Research motivation**

Although a limited number of case reports on xanthogranulomatous appendicitis (XGA) have been published to date, no systematic literature analysis has been conducted.

**Research objectives**

The main objective of this study was to review the articles published in the medical literature on XGA. A secondary objective of this study was to present the medical history of a female patient diagnosed with XGA.

**Research methods**

A systematic literature search was conducted on PubMed, Medline, Google Scholar, and Google databases using the following keywords: Appendix vermiformis, acute appendicitis, XGA, interval appendectomy, and appendectomy. The search included articles published before May 2020, and the publication language was not restricted.

**Research results**

A total of 29 articles involving 38 patients with XGA, were retrospectively analyzed. A total of 38 patients, 20 (52.6%) female and 18 (47.4%) male, aged from 3 to 78 years were included in this study. Fifteen patients' WBC values were reported, and 13 (86.7%) of them had leukocytosis. Twenty-five patients were diagnosed with acute appendicitis, ruptured appendicitis, or subacute appendicitis, and the remaining 13 patients underwent surgery for tumoral lesions of the ileocecal region. Twenty-two of the patients underwent urgent or semi-urgent surgery, and the remaining 16 patients underwent interval appendectomy.

**Research conclusions**

Xanthogranulomatous inflammation rarely affects the appendix vermiformis. It is associated with significant diagnostic and therapeutic dilemmas due to its variable presentation. It is often associated with interval appendectomies, and a significant number of patients require bowel resection due to the common presentation of a tumoral lesion.

**Research perspectives**

A review of the literature and our experience of appendiceal diseases suggest that XGA is usually identified after histopathological examination of the appendectomy specimen and XGA has no unique features in preoperative diagnostic studies. Therefore, the most important factors regarding the preliminary diagnosis of XGA are surgeon's experience, clinical suspicion and intraoperative findings.

## REFERENCES

- 1 **Cozzutto C**, Carbone A. The xanthogranulomatous process. Xanthogranulomatous inflammation. *Pathol Res Pract* 1988; **183**: 395-402 [PMID: 3054826 DOI: 10.1016/S0344-0338(88)80085-2]
- 2 **Levy M**, Bauml R, Eddy AA. Xanthogranulomatous pyelonephritis in children. Etiology, pathogenesis, clinical and radiologic features, and management. *Clin Pediatr (Phila)* 1994; **33**: 360-366 [PMID: 8200171 DOI: 10.1177/000992289403300609]
- 3 **Munichor M**, Kerner H, Cohen H, Bickel A, Iancu TC. Xanthogranulomatous appendicitis--an incidental finding of localized pathology. *Ultrastruct Pathol* 2000; **24**: 33-39 [PMID: 10721150 DOI: 10.1080/019131200281291]
- 4 **Adhikari A**, Ray RN, Minz RS, Nayek BC. Xanthogranulomatous appendicitis: Entity of surprise. *Arch Med Health Sci* 2018; **6**: 120-121
- 5 **Jusoh AC**, Ghani SA. Xanthogranulomatous lesion in recurrent appendicitis. *Formosan J Surg* 2016; **49**: 114-118 [DOI: 10.1016/j.fjs.2016.01.001]
- 6 **Thapa R**, Gurung P, Kafle N, Pradhanang S, Lakhey M, Singh DR. Xanthogranulomatous appendicitis: A case report. *J Institute of Med* 2017; **38**: 126-128



- 7 **Singh V**, John KM, Malik A, Pareek T, Dutta V. Xanthogranulomatous appendicitis: Uncommon histological variant of a common entity. *Med J Armed Forces India* 2015; **71**: S19-S21 [PMID: 26265827 DOI: 10.1016/j.mjafi.2012.11.003]
- 8 **Omer TA**, El Hassan LAM, El Hassan AM, Fahal AH. A rare presentation of xanthogranulomatous appendicitis and caecal angioliopoma in the same patient. *Sudan Med J* 2011; **47**: 165-168
- 9 **Rogers S**, Slater DN, Anderson JA, Parsons MA. Cutaneous xanthogranulomatous inflammation: a potential indicator of internal disease. *Br J Dermatol* 1992; **126**: 290-293 [PMID: 1554606 DOI: 10.1111/j.1365-2133.1992.tb00661.x]
- 10 **Hoabam S**, Devi KS, Thiyam U. Xanthogranulomatous appendicitis- An uncommon entity. *J Evolution Med Dent Sci* 2017; **6(13)**: 1061-1063 [DOI: 10.14260/Jemds/2017/229]
- 11 **Chandanwale SS**, Dey I, Kaur S, Nair R, Patil AA. Xanthogranulomatous appendicitis mimicking appendicular lump: An uncommon entity. *Clin Cancer Investig J* 2015; **4**: 769-771 [DOI: 10.4103/2278-0513.169116]
- 12 **Al-Rawabdeh SM**, Prasad V, King DR, Kahwash SB. Xanthogranulomatous appendicitis in a child: report of a case and review of the literature. *Case Rep Med* 2013; **2013**: 498191 [PMID: 24093025 DOI: 10.1155/2013/498191]
- 13 **Birch PJ**, Richmond I, Bennett MK. Xanthogranulomatous appendicitis. *Histopathology* 1993; **22**: 597-598 [PMID: 8018123 DOI: 10.1111/j.1365-2559.1993.tb00185.x]
- 14 **Dymock RB**. Pathological changes in the appendix: a review of 1000 cases. *Pathology* 1977; **9**: 331-339 [PMID: 593732 DOI: 10.3109/00313027709094453]
- 15 **Quadri R**, Vasani V, Hester C, Porembka M, Fielding J. Comprehensive review of typical and atypical pathology of the appendix on CT: cases with clinical implications. *Clin Imaging* 2019; **53**: 65-77 [PMID: 30316106 DOI: 10.1016/j.clinimag.2018.08.016]
- 16 **Yang DM**, Kim HC, Kim SW. A Pictorial review of xanthogranulomatous inflammation of various organs in the abdomen and pelvis. European Congress of Radiology February 28–March 4 2018 Vienna, Austria [DOI: 10.1594/ecr2018/C-0410]
- 17 **Kaushik R**, Gulati A, Vedant D, Kaushal V. Cytological diagnosis of xanthogranulomatous appendicitis. *J Cytol* 2017; **34**: 48-50 [PMID: 28182060 DOI: 10.4103/0970-9371.197619]
- 18 **Mehrotra N**, Arakeri SU. Xanthogranulomatous Appendicitis: A Rare Case Report. *JKIMSU* 2017; **6**: 125-128
- 19 **Laiphrakpam A**, Singh KL, Devi LS, Moirangthem G S. Xanthogranulomatous appendicitis: A rare histopathological entity. *J Med Soc* 2017; **31**: 208-210 [DOI: 10.4103/jms.jms\_16\_17]
- 20 **Nam S**, Kang J, Choi SE, Kim YR, Baik SH, Sohn SK. Xanthogranulomatous Appendicitis Mimicking Residual Burkitt's Lymphoma After Chemotherapy. *Ann Coloproctol* 2016; **32**: 83-86 [PMID: 27218100 DOI: 10.3393/ac.2016.32.2.83]
- 21 **Cavusoglu YH**, Ardicli B, Apaydin S, Avsarlar CE, Yilmaz E. Xanthogranulomatous appendicitis in interval appendectomy specimens of children. *J Pediatric Surg Case Rep* 2016; **8**: 27-29 [DOI: 10.1016/j.epsc.2016.03.006]
- 22 **Altay C**, Yavuz E, Egeli T, Canda EA, Sarioglu S, Secil M. Xanthogranulomatous appendicitis causing an endometrial abscess: radiological findings. *Wien Klin Wochenschr* 2015; **127**: 970-973 [PMID: 25412596 DOI: 10.1007/s00508-014-0659-5]
- 23 **Montazer F**, Emadian O, Torabizadeh Z, Majlesi M, Bahari M. Xanthogranulomatous appendicitis an incidental finding. *Int J Med Invest* 2014; **4**: 37-39
- 24 **Kochhar G**, Saha S, Andley M, Kumar A, Kumar A. Xanthogranulomatous appendicitis with a fulminant course: report of a case. *J Clin Diagn Res* 2014; **8**: ND01-ND02 [PMID: 25653988 DOI: 10.7860/JCDR/2014/8660.5230]
- 25 **Mado K**, Mazaki T, Henmi A, Masuda H, Takayama T. Xanthogranulomatous appendicitis. *Indian J Surg* 2013; **75**: 405-406 [PMID: 24426487 DOI: 10.1007/s12262-012-0478-8]
- 26 **Martinez-Garza PA**, Robles LLPA, Visag CVJ, Reyes EL. Xanthogranulomatous appendicitis: report of a case and literature review. *Cir Gen* 2011; **33**: 262-265
- 27 **Omori I**, Kohashi T, Matsugu Y, Nakahara H, Nishisaka T. A case of xanthogranulomatous appendicitis difficult to differentiate from appendiceal cancer. *J Japan Surgical Assoc* 2011; **72**: 409-413 [DOI: 10.3919/jjsa.72.409]
- 28 **Young BC**, Hamar BD, Levine D, Roqué H. Medical management of ruptured appendicitis in pregnancy. *Obstet Gynecol* 2009; **114**: 453-456 [PMID: 19622958 DOI: 10.1097/AOG.0b013e3181998424]
- 29 **Chuang YF**, Cheng TI, Soong TC, Tsou MH. Xanthogranulomatous appendicitis. *J Formos Med Assoc* 2005; **104**: 752-754 [PMID: 16385379]
- 30 **Guo G**, Greenson JK. Histopathology of interval (delayed) appendectomy specimens: strong association with granulomatous and xanthogranulomatous appendicitis. *Am J Surg Pathol* 2003; **27**: 1147-1151 [PMID: 12883248 DOI: 10.1097/00000478-200308000-00013]
- 31 **Khaly-Mawad J**, Greco MA, Schinella RA. Ultrastructural demonstration of intracellular bacteria in xanthogranulomatous pyelonephritis. *Hum Pathol* 1982; **13**: 41-47 [PMID: 7076194 DOI: 10.1016/s0046-8177(82)80137-8]
- 32 **McVey RJ**, McMahon RF. Xanthogranulomatous appendicitis. *Histopathology* 1994; **24**: 198 [PMID: 8181818 DOI: 10.1111/j.1365-2559.1994.tb01311.x]
- 33 **Carr NJ**, Path MRC, Montgomery E. Patterns of Healing in the Appendix. The Morphologic Changes in Resolving Primary Acute Appendicitis and a Comparison With Crohn's Disease. *Int J Surg Pathol* 1994; **2**: 23-30 [DOI: 10.1177/106689699400200105]

- 34 **Kulkarni MP**, Sulhyan KR, Barodawala SM, Yadav DH. Histopathological study of lesions of the appendix. *Int J Health Sci Res* 2017; **7**: 90-95
- 35 **Shaik S**, Jayakumar NM, Manikyam UK. Should every appendicectomy specimen be subjected to histopathological examination? *J Evid Based Med Health* 2017; **4**: 5772-5775 [DOI: [10.18410/jebmh/2017/1162](https://doi.org/10.18410/jebmh/2017/1162)]
- 36 **Al-Zaidi RS**. Xanthogranulomatous Appendicitis: an Unusual Pattern of Appendiceal Inflammation. *Saudi J Pathol Microbiol* 2018; **3**: 115-120 [DOI: [10.21276/sjpm.2018.3.4.4](https://doi.org/10.21276/sjpm.2018.3.4.4)]
- 37 **Laishram S**, Shimray R, Pukhrabam GD, Sarangthem B, Sharma AB. Xanthogranulomatous inflammatory lesions: a 10-year clinicopathological study in a teaching hospital. *Bangladesh J Med Sci* 2014; **13**: 302-305 [DOI: [10.3329/bjms.v13i3.16266](https://doi.org/10.3329/bjms.v13i3.16266)]
- 38 **Rosen MP**, Ding A, Blake MA, Baker ME, Cash BD, Fidler JL, Grant TH, Greene FL, Jones B, Katz DS, Lalani T, Miller FH, Small WC, Spottswood S, Sudakoff GS, Tulchinsky M, Warshauer DM, Yee J, Coley BD. ACR Appropriateness Criteria® right lower quadrant pain--suspected appendicitis. *J Am Coll Radiol* 2011; **8**: 749-755 [PMID: [22051456](https://pubmed.ncbi.nlm.nih.gov/22051456/) DOI: [10.1016/j.jacr.2011.07.010](https://doi.org/10.1016/j.jacr.2011.07.010)]
- 39 **Drake FT**, Flum DR. Improvement in the diagnosis of appendicitis. *Adv Surg* 2013; **47**: 299-328 [PMID: [24298858](https://pubmed.ncbi.nlm.nih.gov/24298858/) DOI: [10.1016/j.yasu.2013.03.003](https://doi.org/10.1016/j.yasu.2013.03.003)]



Published by **Baishideng Publishing Group Inc**  
7041 Koll Center Parkway, Suite 160, Pleasanton, CA 94566, USA

**Telephone:** +1-925-3991568

**E-mail:** [bpgoffice@wjgnet.com](mailto:bpgoffice@wjgnet.com)

**Help Desk:** <https://www.f6publishing.com/helpdesk>

<https://www.wjgnet.com>

