

Original Research Article

A study of the anatomic variations of the pancreatico-biliary system in Palestine: a national study

Hiba Abdelkareem^{1*}, Rola Ali¹, Mukaram Jibrini¹, Zaher Nazzal², Mosab Maree³,
Jihad Hamaida³, Khaled Demyati⁴

¹Department of Medicine, ²Department of Community and Family Medicine, ³Department of Radiology, ⁴Department of Surgery, An-Najah National University Hospital, Nablus, Palestine

Received: 24 February 2019

Accepted: 12 March 2019

*Correspondence:

Dr. Hiba Abdelkareem,

E-mail: hiba.abdelkareem@yahoo.com

Copyright: © the author(s), publisher and licensee Medip Academy. This is an open-access article distributed under the terms of the Creative Commons Attribution Non-Commercial License, which permits unrestricted non-commercial use, distribution, and reproduction in any medium, provided the original work is properly cited.

ABSTRACT

Background: The objective of this study is to assess the frequency of anatomic variations of the biliary system in the Palestinian population in patients undergoing MRCPs.

Methods: For a period of 3 years, from March 2016 to January 2019, a total of 401 MRCPs were performed in different Palestinian Medical Centers for different indications. 346 Images were included in the study. Images were evaluated independently by two expert radiologists for the presence of variations in the anatomy of gallbladder, cystic duct, common bile duct, pancreatic duct, pancreas and intrahepatic ducts.

Results: About 78% of the images had normal anatomy of Intra-hepatic ducts. Right posterior duct joining the right anterior duct by its lateral side was observed in 12.6% of images and triple confluence in 8.5% of images. About 12% of the gallbladder images have anatomical variation; multi-septate in 4.1% of images and ectopic in 3.7% images. For the cystic duct, it was abnormally low in 9.6% of images and high in 5.3% of images. The cystic duct was found parallel in 2.3% of images. Variations of the pancreatic duct were evident in 3.9% of the images.

Conclusions: Anatomical variations of the pancreatico-biliary system are common and they are worth the attention to prevent major complications during hepatobiliary surgeries.

Keywords: Pancreatic-biliary system, Anatomical variations, MRCPs, Palestine

INTRODUCTION

In recent years in Palestine, hepatobiliary surgeries, such as cholecystectomies, liver resections, and partial liver transplantations are increasing in frequency and complexity. This fact calls for a better understanding of biliary anatomy and potential biliary variations. In this article, we present an unprecedented national study that deserves attention in both clinical and surgical settings.

There is no absolute anatomy of the hepto-biliary tract, as only about 60% of humans present with the proposed typical anatomy.¹⁻³ The anatomy of the hepatobiliary system is complex and there are several anatomic

variations, some of them are common and others being less frequent.⁴ Although in the majority of cases the anatomic variations can be asymptomatic these variants, if unrecognized, can increase the probability of unintentional iatrogenic injury during surgical procedures, as cholecystectomy due to inadvertent ligation or transection.⁵ These injuries consecutively can lead to significant morbidity and mortality.⁶ Therefore, familiarity and knowledge of these anatomic variations are highly important for the hepatobiliary surgeons.⁷ A common pattern of verities exists and it is the surgeon's responsibility to recognize these variations when present.^{1,8} In addition, knowing the precise anatomy of the biliary duct is very important in some procedures like

the selection of donors in liver transplantation. For example, one of the contraindications to a safe right hepatectomy is the presence of "triple confluence" and the existence of "right posterior duct" draining into "the left hepatic duct is a contraindication to both right and left hepatectomy."^{4,9}

To identify the anatomic variations, it is absolutely necessary to appreciate the basic knowledge of the embryological development and normal anatomy of the biliary system.¹⁰ The biliary development journey starts in the fourth week of embryonic life in which a hepatic diverticulum gives rise to two buds: The cranial bud that later grows into the liver and the extrahepatic biliary tree and the caudal bud which develops into superior and inferior buds which become the gallbladder and cystic duct, and the right and left ventral pancreas, respectively.¹¹ The intrahepatic development is not fully known with different theories were suggested by different studies.¹²

A variety of imaging modalities have been emerged that may be used to visualize the anatomy of the biliary system such as intravenous cholangiography, Endoscopic retrograde cholangiopancreatography (ERCP), Intraoperative cholangiography and Magnetic resonance cholangiopancreatography (MRCP).¹³ MRCP is a recent and constantly evolving imaging technique that studies the bile and pancreatic duct, with an accuracy reaches 90-95%.^{2,14} It has been preferred over ERCP and other imaging techniques, and have been considered the ideal modality to study the pancteabiliary tract anatomy, as it is noninvasive, ionizing radiation free, does not require anesthesia.^{15,16} For example the common and potentially severe complications of ERCP and their high risk of mortality and morbidity as pancreatitis, hemorrhage, bowel perforation, and infection are not encountered using MRCP.¹⁷ Due to these reasons in this study we relied on MRCP images to demonstrate the anatomic variations and anomalies of the biliary and pancreatic system.

The aim of this study is to detect and document the prevalence of anatomical variations of the biliary system in the Palestinian population, to assess their frequencies and to compare our findings to anatomical variations described elsewhere in the literature as no data are available on this important subject locally.

METHODS

During a period of three years, from March 2016 to January 2019, a total of 401 consecutive magnetic resonance cholangiopanographies was performed at three different Palestinian institutions- NNUH, Patients Friend Society Center, and Ramallah hospital. These centers are the main ones in Palestine and they receive patients from all over the region. Sampling method was convenient, including all patients referred for MRCP suspected of

having inflammatory, lithiasic, or neoplastic disease of the hepatobiliary and pancreatic system.

Two professional radiologists, each with over ten years of experience, prospectively assessed the MRCP's and were blinded to the patients' identities. Results obtained from both radiologists were compared to assess the degree of inter observer agreement. Any discrepancy between the reviewers was resolved by a consensus. Structures mainly examined and evaluated were the gallbladder, cystic duct, intrahepatic bile ducts, pancreas, pancreatic duct, major papilla and common bile duct. A detailed analysis was made in regards to their location, shape, length and course. MRCP in these patients was carried out for the purpose of detecting stones causing biliary obstruction, identifying hepatobiliary and pancreatic tumors, staging tumors, assessing iatrogenic biliary injuries, and evaluating congenital biliary anomalies.

Regardless of the underlying cause, the MRCP's were chosen to be included in the study only if opacification of the biliary and pancreatic ducts was adequate, and if the anatomy was clearly visualized. In some images, part of the hepatobiliary system was obscured, yet these MRCP's were still included in the study as other biliary features were clearly visualized and variations were detected. The feature that was obscured was excluded and the study was made accordingly. In view of this, fifty five images were totally excluded from the study, because of unclear and obscured biliary anatomy or because the MR examination did not image the entire biliary tree as required.

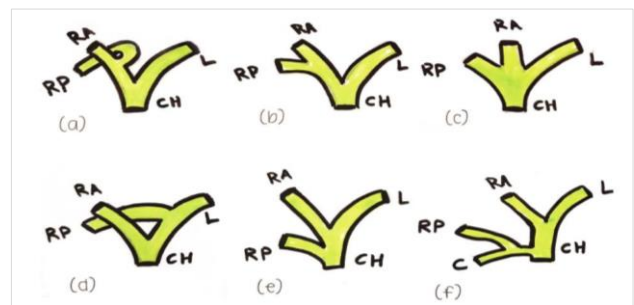


Figure 1: Schematic drawing shows (a) the typical intrahepatic bile ducts anatomy and (b) the anatomic variations; drainage of right posterior duct into right anterior duct on its lateral side, (c) the right anterior and posterior ducts join into a common point with the left duct forming a triple confluence and (d) drainage of right posterior duct into left duct, (e) cystic duct or common hepatic duct (f).

CH=common hepatic duct, RA=right anterior duct, RP= right posterior duct, L=left hepatic duct, C=cystic duct.

The anatomy of intrahepatic bile ducts was labeled normal when the following conditions applied as shown in Figure 1a. First the right posterior duct runs horizontally posterior to the vertically coursed right anterior hepatic duct. Second the posterior duct joins the

anterior in the medial aspect. Third the union of the two ducts forms a common duct, the right hepatic duct. Fourth the right duct integrates the left hepatic duct to form the common hepatic duct (CHD). Any deviation from the above description was considered as anatomic variation. Figure 1 shows the normal intrahepatic bile ducts anatomy (a) and its common anatomical variations.

Normal gallbladder was defined as an elliptical organ lies in the fossa between the right and left lobes of the liver. It was studied for the presence of different variations in its shape and location. Variations include failure in its formation (agenesis), abnormal positioning (ectopic), duplication, bilobing and the presence of a fold or septum between the body and fundus (Phrygian cap), multiseptation and diverticulum.

Cystic duct was defined as the portion that connects the gallbladder to the CHD. It was considered normal if it inserts at the middle third of the CHD from the lateral aspect and ranges 2-4 cm in length. It was evaluated for different anatomical variations regarding its insertion, length, and course. Studied anatomical variations include absence of cystic ducts, duplicated cystic duct, cystic ducts with medial, anterior and posterior aspect of

insertion, higher and lower level of insertion than the normal consideration, shorter and longer cystic ducts than the mentioned length range and a cystic duct with a parallel course to the common hepatic duct extending for 2 cm or more.

A common bile duct (CBD) was defined as the duct which is formed at the junction of the CHD and the cystic duct and joins the pancreatic duct at the ampulla of Vater. It was studied for the presence of any dilation or enlargement represented as choledochal cyst. The absence of a common channel of pancreatic duct and CBD was considered as a variant.

A normal anatomy of pancreatic duct was considered when the main pancreatic duct is divided into two ducts, the duct of Wirsung, which is posterior and drains the ventral pancreas in the major papilla and the accessory duct of Santorini, which is anterior and drains the dorsal pancreas in minor papilla. Failure of fusion of the two duct (pancreatic divisum) Figure 2 (A-C), switching of the site of drainage (ansa pancreatica) Figure 2 (D), bifiding, duplication and cystic dilation of the pancreatic duct were all considered as variations. We also studied different courses of the pancreatic duct Figure 3.

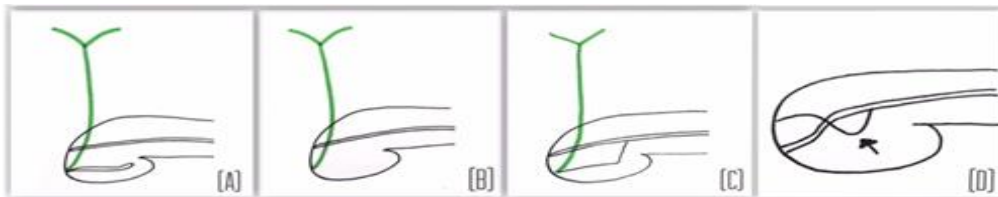


Figure 2: Schematic drawings illustrating some of pancreatic duct variations, A-C show different types of pancreatic divisum, (A) classical: complete failure of fusion between two ducts; (B) with absent ventral duct; (C) with rudimentary communication between ventral and dorsal duct; (D) Ansa pancreatica in which dorsal pancreatic duct: duct of Wirsung (arrowed) forming a reverse S shape then enter the minor papilla.




Figure 3: Schematic drawings illustrating different pancreatic duct courses, (A) descending, (B) sigmoid, (C) vertical and (D) looped.

A normal pancreas was defined as a J shaped organ lies transversely in the posterior abdomen. It was studied for the presence of different anatomical variations including agenesis, ectopic pancreas, annular pancreas, accessory pancreatic lobe, hypoplasia of the dorsal pancreas and pancreatic cysts.

MRCP technique

All MRCPs were performed by using a 1.5T scanner (Philips Ingenia). MR examinations were made including

axial thick slice turbo spin echo (TSE) with parameters of TR 400, TE 80, voxel size of slice thickness 6 mm×1.4 mm×1.6 mm. Flip angle is 90 degree.

Dimensions of frequency and phase encodings and number of slices are patient dependent, which should cover the abdomen AP and RL and FH. NSA is 1 with no fat suppression. The other sequence is called MRCP 3D HR designed to show the biliary system. TR is 1024 TE600 with voxel size 1×1×0.9 slice thickness. NSA with fat suppression. Both sequences done with respiratory

trigger for respiratory compensation. Date of images is processed to reconstruct maximum intensity projection (MIP) images and multiplanar reformatted images (MPR).

Statistical analysis

SPSS statistical software was used for data entry and analysis. Frequency and percentages for categorical variables was computed and presented in tables and figures. Chi square test was used to compare the anatomic variation between male and female groups. A p-value of less than 0.05 was considered significant.

The study was ethically approved and permissions were taken from the different hospitals.

RESULTS

A total of 346 MRCP images were assessed for hepatobiliary system anatomical variations, 189 were females (54.1%) and 157 were males (45.3%), with a male to female ratio of 0.83:1. Their ages ranged from 5 to 89 years, with a mean of 51.8 years. Among the studied images, 43.35% had the proposed normal anatomy.

Intrahepatic ducts variations

Intrahepatic ducts were observed in 342 images out of the 364 images included in the study. Of them 266 (77.8%) images had normal anatomy. Anatomical variations of the intrahepatic duct were documented as right posterior duct joining the right anterior duct by its lateral side in 43 images (12.6%), Right posterior duct draining into the left hepatic duct (Figure 4) in 2 images (0.6%), triple confluence in 29 images (8.5%), right posterior duct draining directly into the cystic duct in 1 image (0.3%) and right posterior duct draining directly into the common hepatic duct in 1 image (Figure 5).

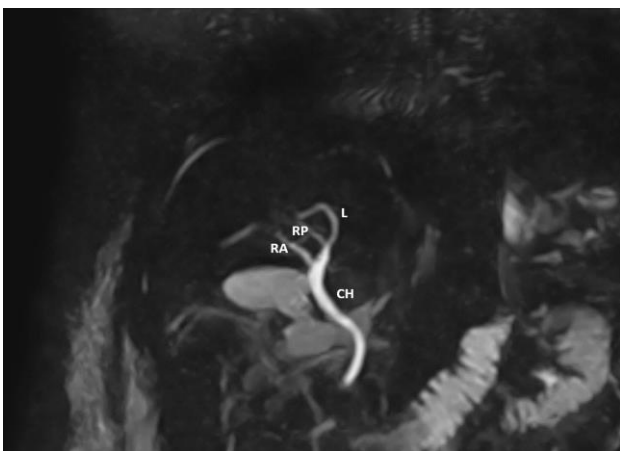


Figure 4: MRCP image shows right posterior duct draining into the left hepatic duct.

CH=common hepatic duct, RA= right anterior duct, RP= right posterior duct, L= left hepatic duct.

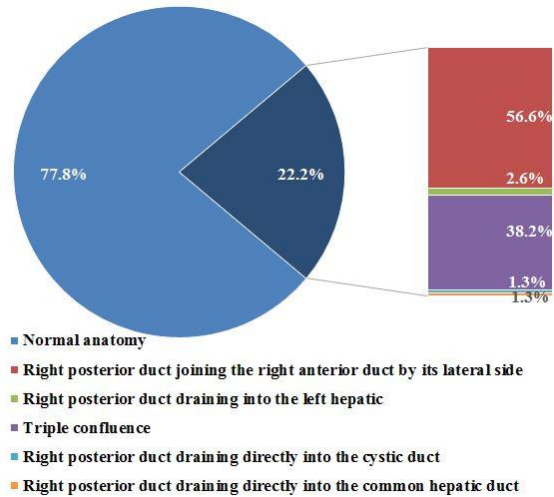


Figure 5: Distribution of intrahepatic ducts normal anatomy and variations.

Gallbladder variations

Regarding the gallbladder, it was visualized in 242 images out of the whole studied images (346 images). It was normal in 216 images (89.3%), bilobed in 1 image (0.4%), ectopic in 9 images (3.7%), with Phrygian cap (Figure 6A) in 9 images (3.7%), diverticular in 3 images (1.2%), and multi-septate (Figure 6B) in 10 images (4.1%) (Figure 7).

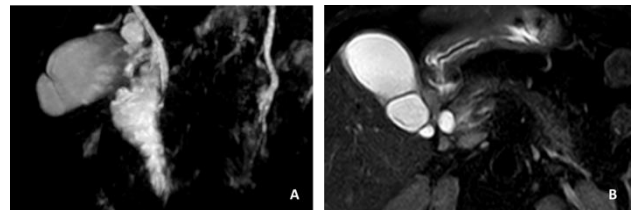


Figure 6: MRCP images show some variations in the anatomy of gallbladder, (A) Phrygian cap and (B) multi-septate gallbladder.

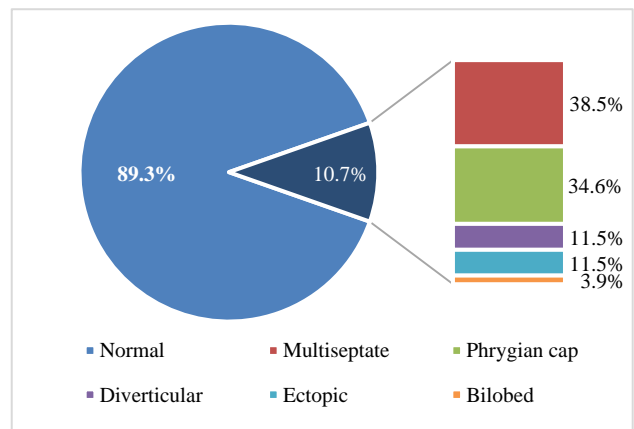


Figure 7: Distribution of gallbladder normal anatomy and variations.

We found a significant association ($p=0.04$) between the existence of varied anatomy and pathological gallbladders in males. The number of males who have gallbladder anatomical variations and pathology at the same time was 15, while in females the number was 11. Pathology includes stones, sludge, wall thickening, acute/chronic inflammation, distention, tumor or cyst.

Cystic duct variations

The cystic duct was evaluated for its level of insertion, site of insertion, length and parallelism. The MRCP was adequate for evaluation 302 images. Of them, in general 228 (75.5%) images showed normal anatomy and the remaining 74 (24.5%) images had anatomical variations (Figure 8).

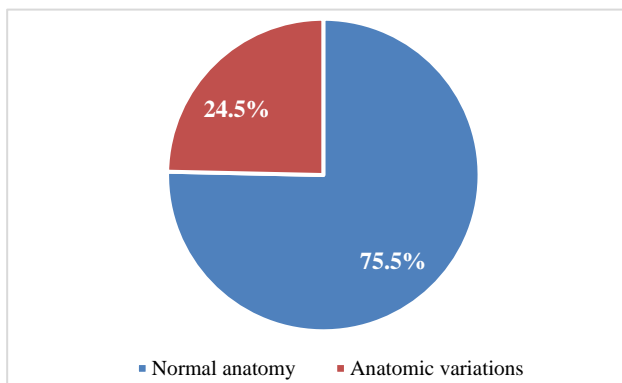


Figure 8: Distribution of cystic duct normal anatomy and variations.

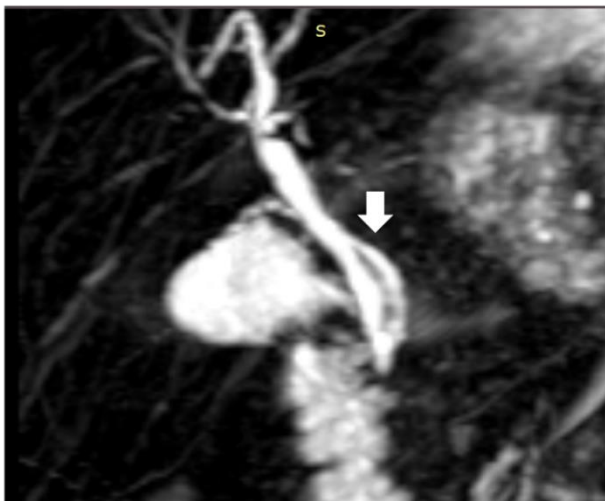


Figure 9: MRCP image shows medial insertion of cystic duct (arrow).

For the cystic duct insertion it was found to be normal (middle) in 257 images (85.1%), low in 29 images (9.6%) and high in 16 images (5.3%). Regarding its site of insertion, it was lateral (normal) in 270 images (89.4%), medial (Figure 9) in 20 images (6.6%), anterior in 5 images (1.7%) and posterior in 7 images (2.3%). The

cystic duct was found to be parallel in 8 (2.3%), and not parallel (normal) in 294 (85%). As for the length, it was normal in 274 images (90.7%), short in 7 (2.3%), and long in 21 (7%).

CBD and major duodenal papilla variations

According to common bile duct, it was normal in 336 out of 340 (98.8%), and a choledochal cyst was found in 4 images (1.2%). The MRCP successfully depicted the major duodenal papilla in 345 images. Of these 345 images, it was normal in 335 images (97.1%) while 10 images (2.9%) had no common channel.

Pancreatic duct variations

Variations of the pancreatic ducts were evident in 13 (3.9%) of the 341 images in which the pancreatic duct was visualized. In particular the MRCP showed divisum classical in 4 (1.2%), divisum absent in 5 (1.5%), divisum incomplete in 2 (0.6%) and ansa pancreatica in 2 images (0.6%) (Figure 10).

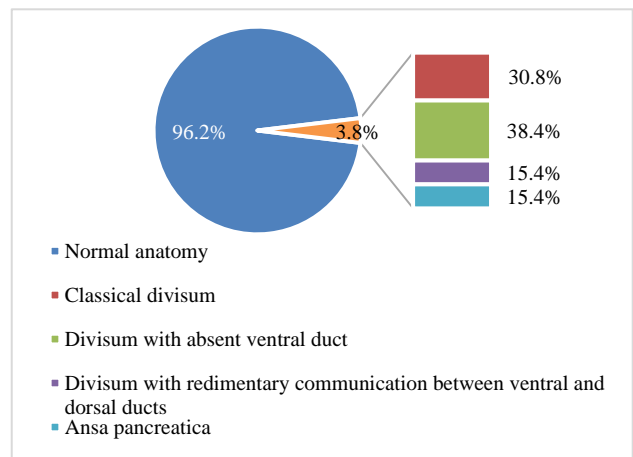


Figure 10: Distribution of pancreatic duct normal anatomy and variations.

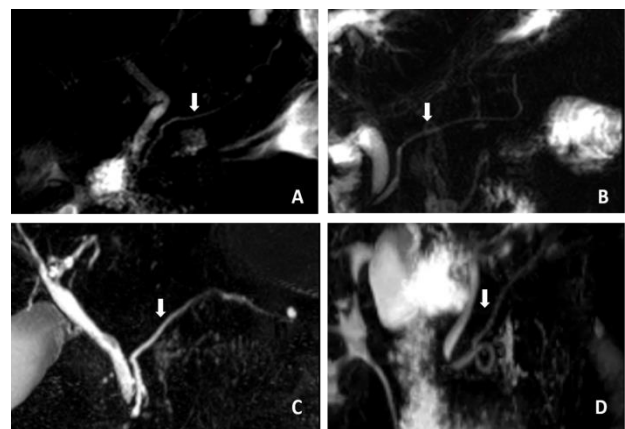


Figure 11: MRCP images show different courses of the main pancreatic duct (arrow); (A) descending, (B) sigmoid, (C) vertical, and (D) looped.

The course of pancreatic duct was descending in 258 (75.4%), sigmoid in 65 (18.7%), vertical in 15 (4.4%) and loop in 4 (1.2%) (Figure 11).

We were able to visualize the pancreas in 343 images and it was normal in all of them.

Table 1: Hepatobiliary system anatomical variations in relation to gender.

Hepatobiliary system	Males frequency (%)	Females frequency (%)	P value
Intra-hepatic bile ducts			
Normal	121 (35.3)	145 (42.4)	0.749
Abnormal	33 (9.6)	43 (12.5)	
Gallbladder			
Normal	99 (40.9)	117 (48.1)	0.252
Abnormal	15 (6.19)	11 (5.5)	
Cystic duct			
Normal	101 (33.4)	127 (42.0)	0.514
Abnormal	36 (11.9)	38 (12.5)	
Cystic duct site of insertion			
Normal	120 (39.7)	150 (49.6)	0.647
Abnormal	17 (5.6)	15 (4.96)	
Cystic duct level insertion			
Normal	116 (38.4)	141 (46.6)	0.982
Abnormal	21 (6.95)	24 (7.94)	
Cystic duct length			
Normal	123 (40.7)	151 (50)	0.875
Abnormal	14 (4.63)	14 (4.63)	
Cystic duct parallelism			
Normal	132 (43.7)	162 (53.64)	0.615
Abnormal	5 (1.65)	3 (0.99)	
Pancreatic duct			
Normal	148 (43.4)	180 (52.7)	0.942
Abnormal	6 (1.76)	7 (2.02)	
Common bile duct			
Normal	151 (44.4)	185 (54.4)	0.425
Abnormal	1 (0.29)	3 (0.88)	

Table 2: The distribution of the pancreatic duct course types.

	Number of variations	Female	Male
	N (%)	N (%)	N (%)
Descending type	259 (75.7)	142 (75.5)	117 (75.9)
Sigmoid type	64 (18.7)	39 (20.7)	25 (16.2)
Vertical type	15 (4.38)	7 (3.7)	8 (5.19)
Loop type	4 (1.16)	0 (0)	4 (2.59)
total	342	188	154

The anatomical variations of hepatobiliary system was studied in relation to gender (Table 1). No significant difference was found between gender and the variables.

We found a significant difference in loop pancreatic duct between males and females ($p=0.026$). 4 males were documented to have a loop course with no documented cases in females. No significant difference was found with other pancreatic duct courses (Table 2).

DISCUSSION

A thorough knowledge and complete understanding of the normal hepatobiliary tract is of fundamental importance for hepatobiliary surgeons and should not be overlooked. A surgeon can encounter different anomalies intraoperatively, in the form of absence, aplasia, and abnormal drainage of ducts, which he/she should be aware of. Failure to recognize these anomalies can have deleterious consequences for the patient. For instance,

complete transection of the CBD occurs when it is mistaken for the cystic duct, and it is one of the dreaded complications of laparoscopic and open cholecystectomy.¹⁸ Accurate preoperative delineation and assessment of the biliary anatomy is thus necessary to ensure safe and successful percutaneous, endoscopic, and surgical procedures. Such surgical procedures can range from the more commonly and routinely performed cholecystectomies, to the more complex surgeries as tumor resection, partial hepatectomy, and liver transplantation.

MRCP is an always evolving imaging technique that is used to optimally image the biliary and pancreatic ductal anatomy.⁴ It is non-invasive, ionizing radiation free, and does not require any anesthesia.⁴ Studies have revealed that preoperative MRCP provides substantial information regarding cystic duct anatomy and has a key safeguarding effect on laparoscopic cholecystectomy.¹⁸ In addition to the fact that it helps avoid iatrogenic injuries, preoperative identification of bile duct anatomy may also help in medicolegal purposes.¹⁸

In the present study, MRCP demonstrated biliary and pancreatic duct anatomical variations in 43.35% of patients. Compared to other regions of the world, this frequency is similar, as according to the literature, the incidence of the normal pattern of the biliary system has been reported to be 57%-72%.¹⁹ This highlights the importance of our study and stresses its implications for hepatobiliary surgery.

A wide variability is noted in the course of the cystic duct and its junction with the extrahepatic bile duct. Classical anatomy of the cystic duct is joining the common hepatic duct at its middle third from the lateral aspect; this is seen in 58%-75% of cases.²⁰ In our study, we have seen this anatomy in 85.1% of our cases. In the study of Sarawagi et al, they had this classical anatomy in 51.5% of their cases.¹⁸

Low insertion of the cystic duct was observed in 9 to 11% of cases in previous studies.^{14,21} The study of Sarawagi et al reported 9% of its cases as having low insertion of the cystic duct.¹⁸ Similarly, our study revealed LICD in 9.6% of our cases. A study conducted in Italy by De Filippo et al reported low insertion of the cystic duct in 4.5% of its cases.⁵

Medial insertion of the cystic duct (MICD) was reported in 10-18% of cases in previous studies.²² This variant is important during surgical procedures, as dissection of the medial cystic duct up to its end is considered unsafe and it is recommended to leave a long remnant of the cystic duct.¹⁰ In our study, we have seen a MICD in 6.6% of our cases.

Parallel course of the cystic duct was reported in 7.5% cases of a study conducted in Pakistan.¹⁸ It was seen to be

found in 4% of cases in an Indian study.²³ Our study has seen it in 2.3% of its cases.

Bilobed gallbladder was reported in 0.4% of its cases. A study conducted by Nadeem in UAE reported bilobed gallbladder in 2% of its cases.²⁴ Septate gallbladder was noted in 4.1% of our cases, a finding that is in concordance with Blumberg, Spech et al, where the incidence of septate gallbladder was also 4%.^{25,26}

A study conducted in Turkey by Zehra and her colleagues reported variations in the course of the pancreatic duct. Results showed 62.5% for descending versus 75.4% at our present study, 30% for sigmoid versus 18.7% at our present study, 5.5% for vertical versus 4.4% at our present study and 2% for loop versus 1.2% at our present study.²⁷

In Korea, a study was carried out to detect anomalies of the pancreaticobiliary ducts of Koreans. Choledocal cyst was identified in 0.32% of its cases versus 1.2% in the current study. The clinical significance of this anomaly lies in the remarkably high incidence of malignant transformation in the wall of the cyst.²⁸

A study conducted in Taiwan, has shown that drainage of the right posterior segment into the left hepatic duct before its confluence with the right anterior segmental duct was the most frequent anatomical variation of the intrahepatic biliary system with a prevalence of 13.0%.¹⁹ This is contrary to findings in our present study, which revealed this anatomic variant in only 0.6% of its cases. Triple confluence is characterized by emptying of the right anterior segmental duct, right posterior segmental duct, and left hepatic duct into the common hepatic duct simultaneously. The study of Sinyi et al in China revealed triple confluence in 9.1% of its cases, as compared to 8.5% in our study.¹⁹ Another study conducted in Europe-France by Denis Casting reported triple confluence in 12% of its cases.²⁹ Similarly, Koenrad et al from the United States reported the prevalence of triple confluence as 11% in a pictorial essay.⁷ In the Middle East three studies were conducted in Iran, Saudi Arabia and turkey and found the prevalence of this variant to be 21.5%, 10.7%, and 8.01%, respectively.³⁰⁻³² These results do not seem to follow a certain geographic pattern.

In the current study, no correlation has been noted between anatomical variations and gender, except in the pancreatic duct course (loop); a statistically significant association has been found between gender and looped pancreatic duct course with a p value of 0.026. This variant was present only in males in the present study. In comparison to this, Zehra et al. concluded in their study a statistically significant association between gender and pancreatic duct vertical course (p=0.004), with a higher frequency in females than males, and no significant association was noted with other pancreatic duct course.²⁷

CONCLUSION

Anomalies and variations of the pancreatobiliary system are relatively common, in which the standard, so called normal anatomy was found in 56.64% of patients. This accentuates the significance of recognizing these anomalies prior to and during surgeries, to avoid unnecessary and preventable iatrogenic injuries and complications.

ACKNOWLEDGEMENTS

The researchers would like to thank the radiologic technicians in different Palestinian centers for their help in the process of collecting and saving the MRCPs images.

Funding: No funding sources

Conflict of interest: None declared

Ethical approval: The study was approved by the Institutional Ethics Committee

REFERENCES

- Adams DB. The importance of extrahepatic biliary anatomy in preventing complications at laparoscopic cholecystectomy. *Surg Clin North Am.* 1993;73(4):861-71.
- Griffin N, Charles-Edwards G, Grant LA. Magnetic resonance cholangiopancreatography: the ABC of MRCP. *Insights into imaging.* 2011;3(1):11-21.
- Cachoeira E, Rivas A, Gabrielli C. Anatomic variations of extrahepatic bile ducts and evaluation of the length of ducts composing the cystohepatic triangle. *Int J Morphol.* 2012;30:279-83.
- Ressurreição J, Batista L, Soares JT, Marques I, Matos E, Andrade L, et al. Normal anatomy and anatomic variants of the biliary tree and pancreatic ductal system at MRCP - what the clinicians want to know. *European Soc Radiol.* 2014: 1-38.
- De Filippo M, Calabrese M, Quinto S, Rastelli A, Bertellini A, Martora R, et al. Congenital anomalies and variations of the bile and pancreatic ducts: magnetic resonance cholangiopancreatography findings, epidemiology and clinical significance. *Radiol Med.* 2008;113(6):841-59.
- Nagral S. Anatomy relevant to cholecystectomy. *J Minimal Access Surg.* 2005;1(2):53-8.
- Mortelé KJ, Ros PR. Anatomic Variants of the Biliary Tree. *Am J Roentgenol.* 2001;177(2):389-94.
- Rajguru J, Khare S, Jain S, Ghai R, Singla M, Goel P, et al. Variations in the External Morphology of Gall Bladder. *Elsevier.* 2012;61:9-12.
- Song GW, Lee SG, Hwang S, Sung GB, Park KM, Kim KH, et al. Preoperative evaluation of biliary anatomy of donor in living donor liver transplantation by conventional nonenhanced magnetic resonance cholangiography. *Transpl Int.* 2007;20(2):167-73.
- Mortele KJ, Rocha TC, Streeter JL, Taylor AJ. Multimodality imaging of pancreatic and biliary congenital anomalies. *Radiographics.* 2006;26(3):715-31.
- Ando H. Embryology of the biliary tract. *Dig Surg.* 2010;27(2):87-9.
- Roskams T, Desmet V. Embryology of extra- and intrahepatic bile ducts, the ductal plate. *Anat Rec (Hoboken).* 2008;291(6):628-35.
- Sureka B, Bansal K, Patidar Y, Arora A. Magnetic resonance cholangiographic evaluation of intrahepatic and extrahepatic bile duct variations. *Indian J Radiol Imaging.* 2016;26(1):22-32.
- Taourel P, Bret PM, Reinhold C, Barkun AN, Atri M. Anatomic variants of the biliary tree: diagnosis with MR cholangiopancreatography. *Radiology.* 1996;199(2):521-7.
- Deka P, Islam M, Jindal D, Kumar N, Arora A, Negi SS. Analysis of biliary anatomy according to different classification systems. *Indian J Gastroenterol.* 2014;33(1):23-30.
- Hossary SH, Zytoon AA, Eid M, Hamed A, Sharaan M, Ebrahim AA. MR cholangiopancreatography of the pancreas and biliary system: a review of the current applications. *Curr Probl Diagn Radiol.* 2014;43(1):1-13.
- Andriulli A, Loperfido S, Napolitano G, Niro G, Valvano MR, Spirito F, et al. Incidence Rates of Post-ERCP Complications: A Systematic Survey of Prospective Studies. *Am J Gastroenterol.* 2007;102:1781-8.
- Sarawagi, R, Sundar S, Gupta SK, Raghuwanshi S. Anatomical Variations of Cystic Ducts in Magnetic Resonance Cholangiopancreatography and Clinical Implications. *J Radiol Resd Pract.* 2016;2016:3021484:6.
- Lyu SY, Pan KT, Chu SY, Hsu MY, Chen CM, Hung CF, et al. Common and rare variants of the biliary tree: Magnetic resonance cholangiographic findings and clinical implications. *J Radiol Sci.* 2012;37:59-67.
- Talpur KA, Laghari AA, Yousfani SA, Malik AM, Memon AI, Khan SA. Anatomical variations and congenital anomalies of extra hepatic biliary system encountered during laparoscopic cholecystectomy. *J Pak Med Assoc.* 2010;60(2):89-93.
- Tsitouridis I, Lazaraki G, Papastergiou C, Pagalos E, Germanidis G. Low conjunction of the cystic duct with the common bile duct: does it correlate with the formation of common bile duct stones? *Surg Endosc.* 2007;21(1):48-52.
- Mortele KJ, Ros PR. Anatomic variants of the biliary tree: MR cholangiographic findings and clinical applications. *AJR Am J Roentgenol.* 2001;177(2):389-94.
- Nigam GL, Lalwani R, Ramesh Babu CS, Chauhan C. Surgical anatomy of sub-hepatic biliary system. *J Anatomical Soc India.* 2014;63(1):48-51.

24. Nadeem G. A Study of the Clinico-Anatomical Variations in the Shape and Size of Gallbladder. *J Morphological Sci.* 2016;33:62-7.
25. Blumberg NA. Transverse septum of the gallbladder. *S Afr J Surg.* 1981;19(2):139-43.
26. Spech HJ, Hummer N, Braun H. Septate gallbladder (author's transl). *Med Klin.* 1975;70(21):941-6.
27. Adibelli ZH, Adatepe M, Imamoglu C, Esen OS, Erkan N, Yildirim M. Anatomic variations of the pancreatic duct and their relevance with the Cambridge classification system:MRCP findings of 1158 consecutive patients. *Radiol Oncol.* 2016;50(4):370-7.
28. Kim HJ, Kim MH, Lee SK, Seo DW, Kim YT, Lee DK, et al. Normal structure, variations, and anomalies of the pancreaticobiliary ducts of Koreans:a nationwide cooperative prospective study. *Gastrointest Endosc.* 2002;55(7):889-96.
29. Castaing D. Surgical anatomy of the biliary tract. *HPB: the official journal of the International Hepato Pancreato Biliary Association.* 2008;10(2):72-6.
30. Taghavi SA, Niknam R, Alavi SE, Ejtehad F, Sivandzadeh GR, Eshraghian A. Anatomical Variations of the Biliary Tree Found with Endoscopic Retrograde Cholangiopancreatography in a Referral Center in Southern Iran. *Middle East J Digest Dis.* 2017;9(4):201-5.
31. Al-Jiffry B. Anatomic variations of intra- and extra-hepatic biliary system in the Kingdom of Saudi Arabia. 2015;4(3):147-50.
32. Uysal F, Obuz F, Uçar A, Seçil M, Igci E, Dicle O. Anatomic Variations of the Intrahepatic Bile Ducts: Analysis of Magnetic Resonance Cholangiopancreatography in 1,011 Consecutive Patients. 2014;89:194-200.

Cite this article as: Abdelkareem H, Ali R, Jibrini M, Nazzal Z, Maree M, Hamaida J, et al. A study of the anatomic variations of the pancreatico-biliary system in Palestine: a national study. *Int Surg J* 2019;6:1020-8.