



3-1-2025

Genetics of Frontotemporal Dementia: An Updated Overview

Mustafa Ghanim

Department of Biomedical Sciences, Faculty of Medicine and Health Sciences, An-Najah National University, P. O. Box 7, Nablus, Palestine.

Mohammad Abuawad

Department of Biomedical Sciences, Faculty of Medicine and Health Sciences, An-Najah National University, P. O. Box 7, Nablus, Palestine.

Malik Alqub

Department of Biomedical Sciences, Faculty of Medicine and Health Sciences, An-Najah National University, P. O. Box 7, Nablus, Palestine.

Majdi Dwikat

Department of Allied and Applied Medical Sciences, Faculty of Medicine and Health Sciences, An-Najah National University, P. O. Box 7, Nablus, Palestine.

Samar Alkhaldi

Department of Allied and Applied Medical Sciences, Faculty of Medicine and Health Sciences, An-Najah National University, P. O. Box 7, Nablus, Palestine.

Follow this and additional works at: <https://pmpj.najah.edu/journal>

 [next page for additional authors](#)

Part of the [Genetic Processes Commons](#), [Genetic Structures Commons](#), and the [Pharmacy and Pharmaceutical Sciences Commons](#)

Recommended Citation

Ghanim, Mustafa; Abuawad, Mohammad; Alqub, Malik; Dwikat, Majdi; Alkhaldi, Samar; and Rabaya, Doaa (2025) "Genetics of Frontotemporal Dementia: An Updated Overview," *Palestinian Medical and Pharmaceutical Journal*: Vol. 10 : Iss. 1 , Article 7.

This Research article is brought to you for free and open access by Palestinian Medical and Pharmaceutical Journal. It has been accepted for inclusion in Palestinian Medical and Pharmaceutical Journal by an authorized editor of Palestinian Medical and Pharmaceutical Journal. For more information, please contact mqneibi@najah.edu.

Genetics of Frontotemporal Dementia: An Updated Overview

Abstract

Frontotemporal dementia (FTD) involves a category of disorders characterized by behavioral, linguistic, and mobility abnormalities resulting from neurodegeneration in the frontal and temporal lobes. FTD represents the second most common etiology of early-onset dementia, and is distinguished by a wide range of clinical features. Indeed, three clinical variants are well known: the behavioral variant (bvFTD), which is the most prevalent and predominantly associated with personality and behavioral changes, the semantic variant primary progressive aphasia (svPPA), which is associated with gradual loss of speech integrity and word meaning, and the non-fluent variant primary progressive aphasia (nfvPPA), in which patients have difficulties getting words out, with slurred speech and an abnormal voice. About 15% of FTD patients also have another neurodegenerative motor neuron disease, amyotrophic lateral sclerosis (ALS), and this co-occurrence is called FTD-ALS. About half of FTD cases are familial. The most common observed mode of inheritance for familial FTD is autosomal dominant. So far, at least ten causal genes have been implicated in the etiology of FTD. Three of these genes: the microtubule-associated protein tau (*MAPT*), progranulin (*GRN*) and chromosome 9 open reading frame 72 (*C9ORF72*), are the most common and are responsible for more than half of familial FTD. The remaining genes are rarely reported, and the pathological mechanisms of many of them are unclear. The causes of the remainder of the familial FTD proportion, as well as the sporadic FTD, are to be determined. We conclude that despite all the breakthroughs in discovering the etiology of FTD, the majority of work is still to be done. The discovered causal FTD genes give insights toward a better understanding of the clinical and genetic heterogeneity of FTD, and help in its early and correct diagnosis. Despite the current management of FTD relies mainly on supportive treatment several promising clinical trials showed promising results in the correction of the harmful effects caused by the mutant genes.

Keywords

Genetics, FTD, Dementia, Heterogeneity

Cover Page Footnote

The author(s) would like to thank An-Najah National University (www.najah.edu) for the technical support provided to publish the present manuscript.

Authors

Mustafa Ghanim, Mohammad Abuawad, Malik Alqub, Majdi Dwikat, Samar Alkhaldi, and Doaa Rabaya

Genetics of Frontotemporal Dementia: An Updated Overview

Mustafa Ghanim^{1,*}, Mohammad Abuawad¹, Malik Alqub¹, Majdi Dwikat², Samar Alkhaldi² & Doaa Rabaya³

Received: 20th May 2024. Accepted: 29th June 2024. Published: 1st Mar. 2025

ABSTRACT: Frontotemporal dementia (FTD) involves a category of disorders characterized by behavioral, linguistic, and mobility abnormalities resulting from neurodegeneration in the frontal and temporal lobes. FTD represents the second most common etiology of early-onset dementia, and is distinguished by a wide range of clinical features. Indeed, three clinical variants are well known: the behavioral variant (bvFTD), which is the most prevalent and predominantly associated with personality and behavioral changes, the semantic variant primary progressive aphasia (svPPA), which is associated with gradual loss of speech integrity and word meaning, and the non-fluent variant primary progressive aphasia (nfvPPA), in which patients have difficulties getting words out, with slurred speech and an abnormal voice. About 15% of FTD patients also have another neurodegenerative motor neuron disease, amyotrophic lateral sclerosis (ALS), and this co-occurrence is called FTD-ALS. About half of FTD cases are familial. The most common observed mode of inheritance for familial FTD is autosomal dominant. So far, at least ten causal genes have been implicated in the etiology of FTD. Three of these genes: the microtubule-associated protein tau (*MAPT*), progranulin (*GRN*) and chromosome 9 open reading frame 72 (*C9ORF72*), are the most common and are responsible for more than half of familial FTD. The remaining genes are rarely reported, and the pathological mechanisms of many of them are unclear. The causes of the remainder of the familial FTD proportion, as well as the sporadic FTD, are to be determined. We conclude that despite all the breakthroughs in discovering the etiology of FTD, the majority of work is still to be done. The discovered causal FTD genes give insights toward a better understanding of the clinical and genetic heterogeneity of FTD, and help in its early and correct diagnosis. Despite the current management of FTD relies mainly on supportive treatment several promising clinical trials showed promising results in the correction of the harmful effects caused by the mutant genes.

Keyword: Genetics, FTD, Dementia, Heterogeneity.

Background

Frontotemporal dementia (FTD) represents a group of clinical disorders that results due to loss of neurons, predominantly in the frontal and temporal lobes of the brain. FTD is the third most common type of dementia and the second leading cause of early-onset dementia in patients under the age of 65 years. In most cases, the age at onset varies from 45 to 70 years old. FTD alone accounts for around 5% of all dementias [1]. A wide range of psychological and neurological disorders with symptoms similar to those of FTD may lead to misdiagnosis and underestimate the frequency of FTD due to diagnostic challenges. Epidemiological data estimates that FTD affects 15 to 22 per 100,000 in the population [2, 3]. The incidence is 2.2/100,000 between ages 40-49, 3.3/100,000 between ages 50-59, and peaks to 8.9/100,000 between ages 60-69 [2, 4]. It is noteworthy that most of the published research on FTD has relied heavily on data from countries in North America, Western Europe, and Australia [2]. However, in most developing countries, little research about FTD and dementia in general has been published due to several challenges including the lack of funds and resources, the insufficient knowledge, and the unavailability of specialized centers for neurodegenerative disease research [5-7]. FTD affects both sexes, with a small dominance of males [8].

The FTD has a substantial mortality rate, and the average survival time varies greatly depending on subtype. The typical survival time from diagnosis to death might be as short as three

years for bvFTD patients with motor neuron disease, and up to 12 years for those with svPPA [9]. There is a family history of dementia in roughly 40% of cases of frontotemporal dementia (FTD), and autosomal dominant is the most common mode of inheritance [10-12]. Indeed, in 10-25% of cases, FTD shows an autosomal dominant inheritance pattern [13]. After discovering the link between chromosome 17 and hereditary FTD, a mutation in the microtubule-associated protein tau (*MAPT*) gene, which encodes the tau protein, was discovered in 1998. Notably, tau is a protein identified in the neurofibrillary tangles found in Alzheimer's disease patients' brains. However, this was not Alzheimer's disease because no amyloid plaques were found [14, 15]. The frontal and temporal lobes are responsible for personality, behavior, language learning, motivation, abstract thinking, and executive functions. Therefore, behavioral changes and/or language difficulties are the most prominent clinical manifestations of FTD patients, followed by a decline in executive function and cognitive capacities. FTD refers to a group of neurological conditions that primarily affect the brain's frontal and temporal areas. The anatomical localization is linked to the clinical picture characterized by impairments of social cognition, behavioral changes, executive function deficits, linguistic disorders, and, to a lesser extent, memory impairment.

The definition of FTD has been refined over the course of many years. Prior to the twenty-first century, FTD was divided into three subtypes: behavioral difficulties predominance, progressive nonfluent aphasia [16], and semantic dementia [17]. In 2011, additional diagnostic criteria and subtypes were

1 Department of Biomedical Sciences, Faculty of Medicine and Health Sciences, An-Najah National University, P. O. Box 7, Nablus, Palestine.

* Corresponding author email: mustafa.ghanim@najah.edu

2 Department of Allied and Applied Medical Sciences, Faculty of Medicine and Health Sciences, An-Najah National University, P. O. Box 7, Nablus, Palestine.

3 Faculty of Graduate Studies, An-Najah National University, P. O. Box 7, Nablus, Palestine.

amended and added to the list of available options. Because of this, the FTD was divided into two categories: behavioral variation FTD (bvFTD) and primary progressive aphasia (PPA),

which was further subdivided into two subtypes: the semantic variant (svPPA) and the nonfluent variant (nfvPPA). (Figure 1) [18].

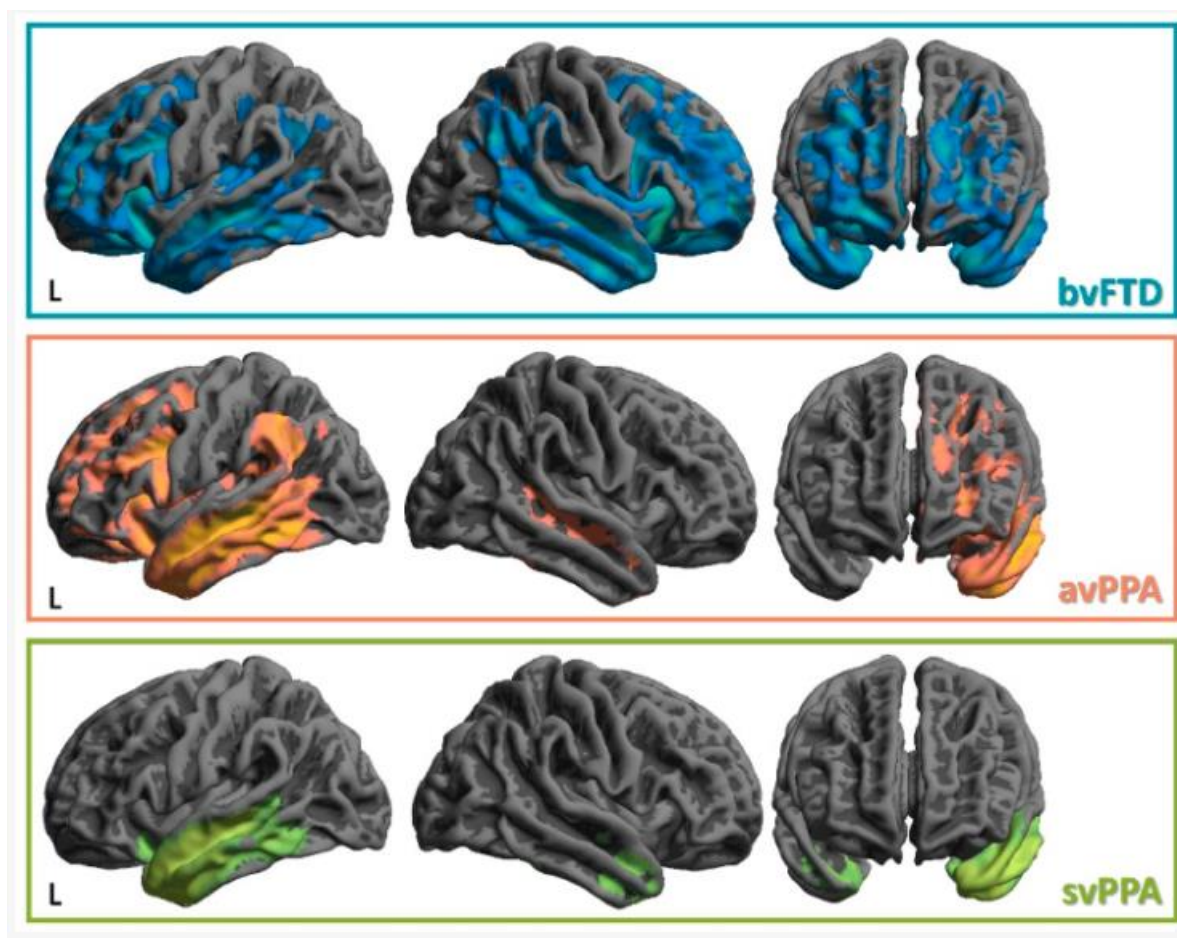


Figure (1): Illustration of patterns of frontal and temporal lobes atrophy in FTD patients by magnetic resonance imaging. The pattern of atrophy is different between these variants but in general they involve the frontal and the temporal lobes. Note: avPPA refers to agrammatic variant of Primary Progressive Aphasia which is the nonfluent variant of primary progressive aphasia that is labeled as nfvPPA in this article [19].

Over the course of several years, a large number of researchers have arrived at the conclusion that FTD may be traced back to its genetic roots. The first locus for FTD was discovered in 1998, and it was demonstrated that mutations in microtubule-associated protein tau (*MAPT*) are responsible for familial FTD with Parkinsonism, which is linked to chromosome 17q21 (FTDP-17) [15]. A number of new mutations have been discovered after the year 2006, including hexanucleotide repeat expansions in the chromosome 9 open reading frame 72 (*C9ORF72*) gene, transactive response DNA-binding protein 43 (*TDP-43*), and the progranulin (*GRN*) gene [20-23]. The mode of inheritance in FTD patients due to mutations in these genes is autosomal dominant.

Three clinical variants of FTD (Figure 2)

bvFTD causes an early and progressive deterioration in social functioning, as well as personality changes. It accounts for almost 50% of all cases of FTD. The hallmark signs of borderline personality disorder are progressive changes in emotional control, behavior, and personality [24, 25]. Patients with bvFTD may present with general lack of self-awareness and lack of empathy and sympathy toward friends or stranger due to lesions in right medial orbitofrontal cortex and anterior part of insula [26, 27], disinhibition due to the involvement of orbitofrontal cortex, repetitive movement suggesting frontosubcortical dysfunction [28], and deficit in executive function due to involvement of dorsolateral prefrontal cortex [29]. Despite the fact that some reports indicate that the right hemisphere is more affected than

the left, the behavioral variation is characterized by localized and significant bilateral frontal atrophy [8, 30]. Phenotypic syndromes, in which a patient has mild autism spectrum disorder or personality problems alongside intact social and emotional functions and no atrophy in magnetic resonance imaging (MRI), and decreased daily functional capacity, both of which can be severe in early stages, are additional symptoms that behavior variant patients may have. Patients may also exhibit hyperorality, changes in nutrition, and repetitive or ritualistic behaviors, as well as perseverative or stereotyped tendencies [4]. Typically, diagnostic criteria are used in conjunction with neuroimaging, cognitive testing, and clinical evaluation to confirm a diagnosis of FTD. The International Consensus Criteria (ICC) guides the diagnosis of bvFTD [31]. The hallmarks of bvFTD include neuroimaging evidence of frontal and/or anterior temporal lobe atrophy, progressive behavioral or personality changes, and cognitive impairment affecting multiple domains. Significant cerebrovascular illness and alternative neurological or psychiatric disorders should be excluded before the diagnosis of bvFTD is established. It should be noted that neuropathological examination after death is usually required to confirm the diagnosis of FTD.

svPPA: represents about 20 to 25 percent [32] of patients with a mean age at symptom onset of 60 years old. Compulsions, loss of language skills, and bilateral anterior temporal lobe atrophy are all symptoms that are typical clinical manifestations of this condition [3, 4, 33]. Furthermore, this condition is

associated with dysfunctional emotional processing. There is a correlation between svPPA and semantic information loss, which is described as the loss of object knowledge, impoverished content, semantic and paraphasic mistake. Neuroimaging research shows asymmetrical bilateral atrophy of the anterior temporal lobe, as well as changes in the left inferior frontal gyrus and posterior superior temporal gyrus. Furthermore, MRI indicated asymmetrical anterior hippocampus atrophy, which is associated to language, compulsions, and dysfunctions in emotional processing [34]. Genetically, svPPA is related with mutations in the *GRN* and *MAPT* genes. [35, 36]. However, genotype-phenotype correlations are complex, with variable clinical presentations even among individuals with the same genetic mutation. The diagnostic criteria for svPPA, outlined by the ICC and the International Behavioral Variant FTD Criteria Consortium (FTDC), emphasize progressive language impairment, relatively preserved other cognitive functions and characteristic neuroimaging findings [37].

nvfPPA is characterized by a noticeable and early symptom of language impairment. This impairment is characterized by apraxia of speech, which causes sluggish speech output due to

a speech motor planning deficit. Additionally, nvfPPA is associated with a condition known as agrammatism in language production. Neuroimaging studies of nvfPPA typically reveal asymmetric atrophy in the left posterior frontal lobe, particularly affecting Broca's area and the supplementary motor area, along with corresponding white matter changes [38-40]. Genetically, nvfPPA is associated with mutations in the *MAPT* gene, and the *C9ORF72* gene [35, 41, 42]. The diagnostic criteria for nvfPPA, outlined by the ICC and the FTDC, emphasize progressive non-fluent language impairment, relatively preserved other cognitive functions, and characteristic neuroimaging findings.

Several research and centers have found a higher prevalence of bvFTD in males [2, 43]. Males are more likely to have svPPA, while females are more likely to have nvfPPA [44]. The median survival time from diagnosis to death varies from three years for bvFTD patients with motor neuron disease to twelve years for those with svPPA [9].

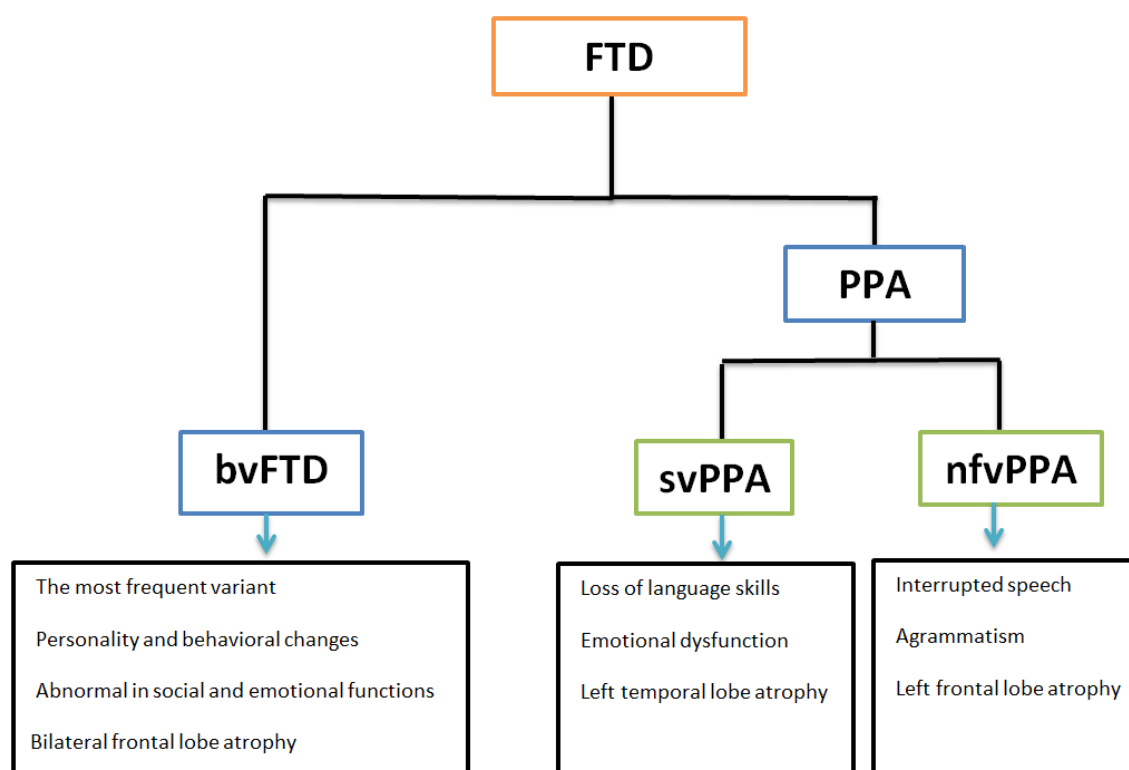


Figure (2): The three clinical variants of FTD with their characteristics and the predominantly affected brain are in each variant.

Association between FTD and ALS

ALS is a fatal type of motor neuron disease caused by irreversible neurodegeneration of nerve cells in the spinal cord and brain. ALS has great overlap with FTD both in terms of clinical manifestations, neuropathological features, and more interestingly the genetic aspects [45]. About 15% of patients with ALS have also FTD, and the same percentage of FTD patients have also ALS. Nevertheless, the explanation of the co-occurrence of both disorders in the same patient is not fully understood. It is believed that ALS and FTD are both ends of the same disorder [46-48].

Genetics of FTD

FTD is a heritable neurodegenerative disease characterized by significant clinical, pathological, and genetic variations. [49]. This is supported by the fact that approximately 25-50% of FTD

patients reported a positive family history of dementia or related neurodegenerative disorders. Autosomal dominant transmission was the most frequently identified mode of inheritance [11, 50, 51]. Notably, the heredity of FTD varies substantially depending on the clinical phenotype. The bvFTD was shown to be the most frequent heritable variation [52], while svPPA is generally considered the least one to have a genetic etiology [52]. Mutations in at least ten genes (Figure 3) were identified as causal in patients with familial FTD. Three of these genes (*MAPT*, *GRN*, *C9ORF72*) represent the most common genes in cases of FTD. Causal mutations in the remaining genes were rarely reported in some families and represented rare causes of FTD and/ or FTD-ALS. The summary of these ten genes is illustrated in Table 1.

Table (1): Summary of genes implicated in the etiology of FTD with their characteristics.

| Gene | Date of mutation discovery | Mutation frequency | Types of mutations | Mechanism of mutations | Mode of inheritance | Phenotype |
|---------|---|--|---|--|---------------------|---|
| MAPT | First discovered major gene 1998 | 5-20% of familial FTD | Missense, silent, deletion and splice site mutations | Gain of toxic function of tau protein | AD | bvFTD with Parkinsonism |
| GRN | Second discovered major gene 2006 | 5-20% of familial FTD | Nonsense, splice site and frameshift mutations | Loss of function | AD | bvFTD and nvPPA with or without parkinsonism |
| C9ORF72 | Third discovered major gene 2011 | The most frequent, responsible for one third of familial FTD | Hexanucleotide (G4C2) _n repeat expansion | Haploinsufficiency and gain of function | AD | bvFTD and FTD-ALS |
| TARDBP | 2008 | Rare | Missense mutations | Unclear but thought gain of function, haploinsufficiency | AD | bvFTD and svPPA, FTD-ALS |
| CHMP2B | 2005 called FTD3 as it is located on chromosome 3 | Rare, private mutations in Danish and Belgian families | Splice site and nonsense mutations | Loss of function | AD | bvFTD with personality change as the most commonly presentation |
| VCP | 2004 | Rare | Missense mutations | Gain of function, haploinsufficiency | AD | bvFTD and FTD-ALS |
| TBK1 | 2015 | Rare | Missense, inframe deletions, non-sense, frame shift mutations | Loss of function | AD | bvFTD and FTD-ALS |
| FUS | 2009 | Rare | Missense mutations | Unclear but thought gain of function, haploinsufficiency | AD | bvFTD and FTD-ALS |
| SQSTM1 | 2012 | Rare | Missense mutations | Unclear but thought gain of function, haploinsufficiency | AD | bvFTD and FTD-ALS |
| UBQLN2 | 2011 | Rare | Missense mutations | Unclear but thought gain of function, haploinsufficiency | XLD | bvFTD and FTD-ALS |

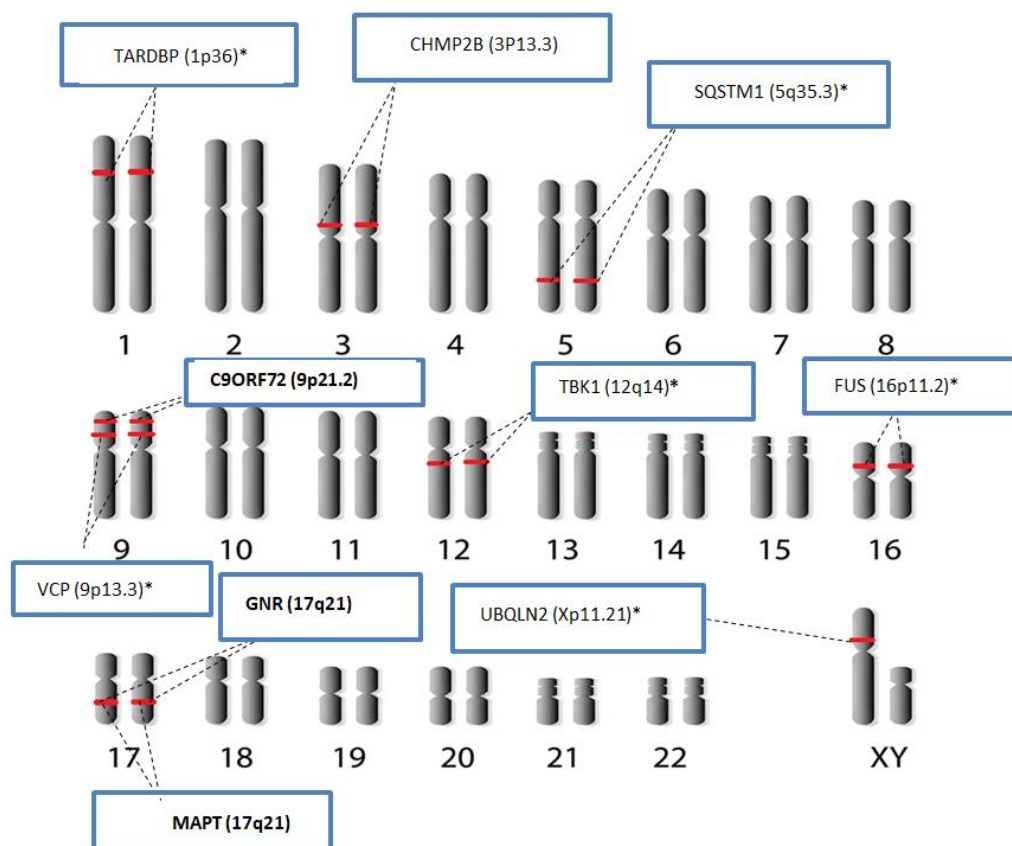


Figure (3): The locations of the ten genes implicated in FTD on human chromosomes. Bolded genes are the common ones in FTD. * Genes which are involved in FTD-ALS.

MAPT gene: The microtubule-associated protein Tau (*MAPT*) gene, which is located on the 17q21 chromosome, contains 16 exons [53]. Its transcripts can undergo alternative mRNA splicing to produce six isomers [54]. These isomers are important to enhance the formation of microtubules, as well as to maintain their stability. These microtubules are vital for the integrity of the cytoskeleton and cytoplasmic transport in human cells, including neuronal cells, because this gene is strongly expressed in the nervous system [55]. More than 50 different *MAPT* pathogenic mutations were identified in patients with FTD, particularly in the bvFTD and, to a lesser extent, in the svPPA and nfvPPA which are often associated with the movement disorder Parkinsonism [56]. They showed autosomal dominant mode of inheritance [57]. These different mutations lead to abnormal structure and subsequently gain of toxic function of tau protein, which leads to its abnormal aggregation and disruption of the formation and stability of microtubules [58]. It is noteworthy that certain *MAPT* mutations are causal in rare familial cases of Alzheimer disease [59, 60].

GRN gene: In 2006, a granulin (*GRN*) gene, located very close to *MAPT* gene on 17q21 chromosome, was discovered as causal for FTD [21]. *GRN* gene product is found in several tissues including the central and peripheral nervous system. It acts as a growth factor that is involved in angiogenesis, brain development and synapse functioning. More specifically, it is involved in the survival, growth, maintenance, and differentiation of both neurons and glia [61]. More than 70 different *GRN* mutations were detected in FTD. All *GRN* mutations cause FTD by haploinsufficiency with incomplete penetrance [62, 63]. Lysosome dysfunction in FTD patients was proposed as the main mechanism of pathology in FTD patients with *GRN* loss of function [64]. Moreover, it was reported that lysosome dysfunction might lead to the activation of microglia and the deposition of myelin debris in the central nervous system as proposed mechanisms of the neurodegeneration [65]. *GRN* mutations were mostly found in the bvFTD and nfvPPA with or without movement disorders. *GRN* mutations are associated with great variability in the clinical presentation in patients with FTD [66].

C9ORF72 gene: Hexanucleotide repeat expansions in chromosome 9 open reading frame 72 (*C9ORF72*) gene, located on chromosome 9p21.2, consists of two non-coding exons (1a and 1b) and 10 coding exons (from 2 to 11). Alternative splicing of its transcripts results in the formation of two isoforms: C9-short of 24 kDa and C9-long of 54 kDa [27]. *C9ORF72* transcripts are detectable in most tissues, notably in all brain regions and the spinal cord, and play a role in neuronal axon growth and maintenance of neuronal synapsis integrity [67].

In 2011, a breakthrough in the uncovering of the genetic basis of FTD was achieved by the identification of a hexanucleotide (G4C2)_n repeat expansion in the *C9ORF72* gene as the most frequent mutation in familial FTD [68, 69]. As with other genetic disorders caused by nucleotide repeat expansion, age at onset of FTD patients due to *C9ORF72* mutations varied greatly from 20s to 90s [70, 71]. The clinical presentations of patients with *C9ORF72* mutations vary greatly from very rapidly to slow progressive disease [68, 72, 73]. Several genotype-phenotype relationships in bvFTD can result from *C9ORF72* gene mutations. First, larger repeat expansions cause earlier onset and worse clinical progression. *C9ORF72* repeat expansion is connected to disinhibition, apathy, and social cognitive deficits. *C9ORF72* mutations in bvFTD produce neuronal loss, gliosis, and proteinaceous inclusions including TDP-43 and p62-positive aggregates [68]. It is noteworthy that about one third of patients with *C9ORF72* mutations receive

another diagnosis at the onset due to the atypical clinical presentations [74, 75]. It is proposed that the mechanism by which *C9ORF72* gene mutations lead to FTD include haploinsufficiency through the loss of function of the gene, as well as gain of novel toxic functions including RNA and protein toxicity [76]. It is important to note that the toxicity of *C9ORF72* hexanucleotide repeat expansions was suggested to be the result of a variety of mechanisms, such as the accumulation of toxic cytoplasmic proteins and the formation of RNA foci through phase separation. The *C9ORF72* protein's functionality is significantly impaired as a consequence of these abnormal alterations [77, 78].

Rare genes in FTD

TARDBP gene: TARDBP gene, which is located on 1p36 chromosome, codes TAR DNA-binding protein 43 (TDP43) which has a crucial role in RNA metabolism [79, 80]. Rare missense *TARDBP* mutations were identified in patients with FTD and FTD-ALS [81]. These mutations affect predominantly the C-terminal region inducing the aggregation propensity [82-85].

CHMP2B gene: Charged multivesicular body protein 2B (CHMP2B) gene, located on 3p11.2 chromosome, codes for a protein involved in autophagy and Endo-lysosomal trafficking. Rare autosomal dominant splice site and nonsense mutations were described in Danish and Belgian FTD families with great clinical variability among these patients [86-89]. These mutations affected the C-terminus of the protein. It is proposed that CHMP2B mutations cause accumulation of autophagosomes with ubiquitinated proteins resulting in neurodegeneration [90]. Endosomal-lysosomal dysfunction and ubiquitin-SDP-43 neuronal intranuclear inclusions (NIIs) result from CHMP2B mutations [91-95].

VCP gene: Valosin-containing protein (VCP) gene, which is located on 9p13.3 chromosome, is a highly conserved eukaryotic protein [96, 97]. VCP is widely expressed in several organs including the brain. It belongs to the type II AAA family, which encompasses a variety of cellular processes, such as the regulation of the cell cycle, the maturation of the autophagosome and the ubiquitin-proteasome system [98, 99]. Several missense mutations in VCP were detected in FTD patients. These mutations are suggested to cause neurodegeneration by defects in protein clearance, and autophagy. It is noteworthy that VCP mutations are characterized by phenotypic heterogeneity as different mutations result in different disorders including myopathy, motor neuron disease, Paget, and FTD [100].

TBK1 gene: The TBK1 (TANK binding kinase 1) gene is located on the 12q14 chromosome. It codes for a protein that plays a critical role in several cellular pathways including the selective clearance of mitochondria and regulation of inflammation. Several missense, inframe deletions, non-sense, and frame shift mutations identified in bvFTD and FTD-ALS patients. Behavior, motor and cognitive impairment result from TDP-43 pathology and TBK1 mutations. TBK1 mutations may contribute to neurodegenerative diseases through defective clearance of damaged mitochondria. Indeed, this process is vital in neuronal survival [92, 101-104].

FUS gene: The fused in sarcoma (FUS) gene, which is located on 16p11.2 chromosome, codes for RNA-binding protein. This protein is involved in alternative RNA splicing, RNA translation and transport [105]. Some missense FUS mutations were reported in FTD patients and FTD-ALS patients [106-108]. The aberrant RNA metabolism especially defective splicing pattern was proposed as the cause of neurodegeneration of FUS mutations [109].

SQSTM1 gene: The sequestosome 1 (SQSTM1) gene, which is located on 5q35.3, codes for p62 adaptor protein. This multifunctional protein is involved in vital cellular processes including cell differentiation, apoptosis, transcriptional regulation, and oxidative stress, and ubiquitin-proteasome degradation pathways [110]. Some missense SQSTM1 mutations were rarely reported in the neurodegenerative disorders FTD, ALS, and FTD-ALS patients [111, 112]. It was suggested that the defects in cellular pathways caused by mutant SQSTM1 product result in neurodegeneration [104, 113].

UBQLN2 gene: Several missense mutations were rarely reported in UBQLN2 gene, which is located on the Xp11.21 chromosome, in patients with FTD-ALS. Interestingly, these mutations follow X-linked dominant inheritance [114, 115]. At least, some of these mutations altered the structural and functional characteristics of the resulting protein and showed a clear correlation between the increased tendency to aggregate and its ability to induce neurotoxicity [116-118]. Indeed, it was proved that UBQLN2 encodes a protein that functions in protein quality control and regulation of proteasomal degradation [118].

Diagnosis of FTD: The diagnostic criteria for FTD, both for the behavioral bvFTD variant and the two language variants of FTD (svPPA and nvPPA), were established by international expert consensus.

The clinical diagnosis of bvFTD [37] is established if the patient meets at least three of the following criteria: (I) early disinhibition; (II) apathy or early inertia; (III) early loss of empathy/sympathy; (IV) perseverative, stereotyped, or early compulsive/ritualistic behavior; (V) hyperorality and dietary changes; and (VI) neuropsychological profile with executive dysfunction and relative preservation of episodic memory and visuospatial abilities.

On the other hand, the clinical diagnosis of the language variants of FTD (svPPA and nvPPA) requires fulfilling three core criteria: (1) the presence of a language impairment that interferes with the usage and/or comprehension of words; (2) this language impairment should be the most prominent neurobehavioural deficit that restricted the daily activities during the initial stages of disorder; and (3) the language impairment should be progressive in nature as it is caused by neurodegenerative changes. Furthermore, the pattern of deficits must not be explained by another neurological or psychiatric disorder [119].

The definitive FTD diagnosis is established only when histopathological changes are observed on brain biopsy, post-mortem examination, or by genetic testing with identification of the causal mutation [120]. It is important to rule out any metabolic or infectious disease which has clinical manifestations that overlap or looks like those caused by FTD. To this end, hormonal analysis, liver function tests, appropriate blood and urine tests should be performed. In addition to that, causes of reversible cognitive impairment like vitamin B12 and folic acid deficiency should be taken into consideration [120].

Neuroimaging analyses of FTD patients can be used to confirm the clinical diagnosis and to exclude other neurodegenerative diseases such as Alzheimer disease, Parkinson disease, and ALS with overlapping clinical manifestations. Depending on the mechanism of action, these neuroimaging methods are classified into three categories: structural, functional, and molecular imaging. Structural imaging includes computed tomography (CT) and structural magnetic resonance imaging (MRI), which can show gross neuroanatomical changes. Functional imaging includes positron emission tomography (PET), single-photon emission computed

tomography (SPECT), and functional MRI (fMRI), tests the metabolic activity, regional blood flow, or hemodynamic changes with patient activity. While the molecular imaging measures molecular and, biological, physiological, and cellular events in living neuronal tissues such as testing for specific receptors or protein aggregates. For the diagnosis of FTD, the structural MRI and PET are two of the most commonly used [121].

Structural imaging can be used to test for the abnormalities in the neuroanatomy of the frontotemporal lobes, and to detect any increase in the sulci and fissures. They are also used to check for the presence of any frontotemporal tumors, ventricular dilatation, or cerebrovascular lesions that are associated with symptoms related to FTD [120].

The functional imaging PET can be used to detect areas in the brain that are characterized by hypometabolic activity and a reduction in blood flow [122, 123].

FTD Prognosis, treatment, clinical trials and future perspectives: FTD is a fatal and irreversible condition for which there is no known curative therapy. The median survival age varied greatly according to the clinical presentation. It was the poorest if FTD is associated with motor disease (FTD-ALS) with median survival age of only 2.5 years. On the other hand, the mean survival age was the longest (8 years) in patients with svPPA. In the most common variant (bvFTD) as well as in the nvPPA, the mean survival rate was 8 years after diagnosis of the disorder. Notably, the sex of the patient did not affect the mean survival age [124]. There is no curative treatment to prevent, stop or delay the neurodegeneration in FTD patients until now. Supportive management is offered to patients and is directed to handle the cardinal symptoms and improving the quality of life [125].

Significant research has been done to specify certain biomarkers to help in presymptomatic and early diagnosis. Nevertheless, there is currently no reliable specific biomarker to be tested for FTD [126]. There are ongoing clinical trials with drugs with potential disease-modifying effect. These therapeutic targets are directed towards preventing and clearing tau aggregates, maintaining the normal tau function, restoring progranulin levels; and suppressing the expression of harmful genes [127]. The ongoing promising clinical trials are designed for the three major genetic defects [128]. The use of antisense oligonucleotide (ASO) demonstrated beneficial effects by selective suppression of the toxic *C9ORF72* transcripts containing the expansions but not affecting the normal transcripts of the gene [129]. ASO was also found to be effective to lower the expression and correct the disturbances resulting from *MAPT* mutations in neurodegenerative disorders [130, 131]. On the other and, adeno-associated virus delivery gene therapy is being tested to offer a functional copy of the *GRN* gene in patients having mutations in this gene to correct the normal expression level, and consequently restore the normal functions of the protein [132]. Additional proposed therapeutic options include tau monoclonal antibodies which are beneficial in some *MAPT* mutations [133], and the use of sortilin protein to rescue *GRN* expression level by sortilin-*GRN* interactions [134].

CONCLUSION

FTD is characterized by wide range of clinical variability and genetic heterogeneity. The etiology is still unknown in the majority of FTD patients. Identifying several causal genes of FTD is of great importance as it points towards a significant genetic component of this disease, as well as multiple disease mechanisms that might share common pathological pathways. The accumulation of these discoveries leads the progress of correct and early diagnosis, and the development of drugs that prevent or delay the neurodegeneration as the main pathological

feature of the disorder. Establishing genotype and phenotype correlations in FTD (when present) is particularly important to provide genetic counseling for FTD patients and families. Further studies should be performed to discover additional genetic and environmental factors that impact in the etiology of familial and sporadic FTD.

Disclosure Statement

- **Ethical Approval:** N/A
- **Disclosure:** The authors declare no conflicts of interest that could potentially influence the research findings.
- **Author Contributions:** Each of the authors played a substantial role in this research, including contributions to the conception and study design. Additionally, they were involved in drafting, and revising the article. Furthermore, all authors provided approval for the manuscript's publication, selected the journal for submission, and committed to being accountable for all aspects of this research.
- **Data Sharing Statement:** The data that support the findings of this study are available from the corresponding author upon reasonable request.
- **Funding:** This research paper was conducted without external funding or financial support.
- **Acknowledgement:** The author(s) would like to thank An-Najah National University (www.najah.edu) for the technical support provided to publish the present manuscript.

Open Access

This article is licensed under a Creative Commons Attribution 4.0 International License, which permits use, sharing, adaptation, distribution and reproduction in any medium or format, as long as you give appropriate credit to the original author(s) and the source, provide a link to the Creative Commons licence, and indicate if changes were made. The images or other third party material in this article are included in the article's Creative Commons licence, unless indicated otherwise in a credit line to the material. If material is not included in the article's Creative Commons licence and your intended use is not permitted by statutory regulation or exceeds the permitted use, you will need to obtain permission directly from the copyright holder. To view a copy of this license, visit <https://creativecommons.org/licenses/by-nc/4.0/>

References

- 1] Boaden E, Burnell J, Hives L, Dey P, Clegg A, Lyons MW, et al. Screening for aspiration risk associated with dysphagia in acute stroke. The Cochrane database of systematic reviews. 2021;10(10):Cd012679.
- 2] Onyike CU, Diehl-Schmid J. The epidemiology of frontotemporal dementia. International review of psychiatry (Abingdon, England). 2013;25(2):130-7.
- 3] Khan I, De Jesus O. Frontotemporal Lobe Dementia. StatPearls. Treasure Island (FL) ineligible companies. Disclosure: Orlando De Jesus declares no relevant financial relationships with ineligible companies.: StatPearls Publishing Copyright © 2024, StatPearls Publishing LLC.; 2024.
- 4] Bott NT, Radke A, Stephens ML, Kramer JH. Frontotemporal dementia: diagnosis, deficits and management. Neurodegenerative disease management. 2014;4(6):439-54.
- 5] Mattap SM, Mohan D. The economic burden of dementia in low- and middle-income countries (LMICs): a systematic review. 2022;7(4).
- 6] Piña-Escudero SD, Aguirre GA, Javandel S, Longoria-Ibarrola EM. Caregiving for Patients With Frontotemporal Dementia in Latin America. Frontiers in neurology. 2021;12:665694.
- 7] Abuawad M, Rjoub A. Evaluation of knowledge and attitudes regarding Alzheimer's disease and related dementia among medical students in Palestine: A cross-sectional study. 2024;19(5):e0304012.

- 8] Bang J, Spina S, Miller BL. Frontotemporal dementia. Lancet (London, England). 2015;386(10004):1672-82.
- 9] Roberson ED, Hesse JH, Rose KD, Slama H, Johnson JK, Yaffe K, et al. Frontotemporal dementia progresses to death faster than Alzheimer disease. Neurology. 2005;65(5):719-25.
- 10] Rosso SM, Donker Kaat L, Baks T, Joosse M, de Koning I, Pijnenburg Y, et al. Frontotemporal dementia in The Netherlands: patient characteristics and prevalence estimates from a population-based study. Brain: a journal of neurology. 2003;126(Pt 9):2016-22.
- 11] Goldman JS, Farmer JM, Wood EM, Johnson JK, Boxer A, Neuhaus J, et al. Comparison of family histories in FTLD subtypes and related tauopathies. Neurology. 2005;65(11):1817-9.
- 12] Rohrer JD, Guerreiro R, Vandrovcsa J, Uphill J, Reiman D, Beck J, et al. The heritability and genetics of frontotemporal lobar degeneration. Neurology. 2009;73(18):1451-6.
- 13] Convery R, Mead S, Rohrer JD. Review: Clinical, genetic and neuroimaging features of frontotemporal dementia. 2019;45(1):6-18.
- 14] Foster NL, Wilhelmsen K, Sima AA, Jones MZ, D'Amato CJ, Gilman S. Frontotemporal dementia and parkinsonism linked to chromosome 17: a consensus conference. Conference Participants. Annals of neurology. 1997;41(6):706-15.
- 15] Hutton M, Lendon CL, Rizzu P, Baker M, Froelich S, Houlden H, et al. Association of missense and 5'-splice-site mutations in tau with the inherited dementia FTDP-17. Nature. 1998;393(6686):702-5.
- 16] Neary D, Snowden JS, Gustafson L, Passant U, Stuss D, Black S, et al. Frontotemporal lobar degeneration: a consensus on clinical diagnostic criteria. Neurology. 1998;51(6):1546-54.
- 17] Clinical and neuropathological criteria for frontotemporal dementia. The Lund and Manchester Groups. Journal of neurology, neurosurgery, and psychiatry. 1994;57(4):416-8.
- 18] Kurz A, Kurz C, Ellis K, Lautenschlager NT. What is frontotemporal dementia? Maturitas. 2014;79(2):216-9.
- 19] Pengo M, Premi E, Borroni B. Dissecting the Many Faces of Frontotemporal Dementia: An Imaging Perspective. 2022;23(21).
- 20] Baker M, Mackenzie IR, Pickering-Brown SM, Gass J, Rademakers R, Lindholm C, et al. Mutations in progranulin cause tau-negative frontotemporal dementia linked to chromosome 17. Nature. 2006;442(7105):916-9.
- 21] Cruts M, Gijssels I, van der Zee J, Engelborghs S, Wils H, Pirici D, et al. Null mutations in progranulin cause ubiquitin-positive frontotemporal dementia linked to chromosome 17q21. Nature. 2006;442(7105):920-4.
- 22] Lye YS, Chen YR. TAR DNA-binding protein 43 oligomers in physiology and pathology. 2022;74(8):794-811.
- 23] Hendricks E, Quihuis AM, Hung ST, Chang J, Dorjsuren N, Der B, et al. The C9orf72 repeat expansion alters neurodevelopment. Cell reports. 2023;42(8):112983.
- 24] Seeley WW. Selective functional, regional, and neuronal vulnerability in frontotemporal dementia. Current opinion in neurology. 2008;21(6):701-7.
- 25] Ducharme S, Dols A, Laforce R, Devenney E, Kumfor F, van den Stock J, et al. Recommendations to distinguish behavioural variant frontotemporal dementia from psychiatric disorders. Brain : a journal of neurology. 2020;143(6):1632-50.
- 26] Rankin KP, Gorno-Tempini ML, Allison SC, Stanley CM, Glenn S, Weiner MW, et al. Structural anatomy of empathy in neurodegenerative disease. Brain: a journal of neurology. 2006;129(Pt 11):2945-56.
- 27] Tekin S, Cummings JL. Frontal-subcortical neuronal circuits and clinical neuropsychiatry: an update. Journal of psychosomatic research. 2002;53(2):647-54.
- 28] Perry DC, Whitwell JL, Boeve BF, Pankratz VS, Knopman DS, Petersen RC, et al. Voxel-based morphometry in patients with obsessive-compulsive behaviors in behavioral variant frontotemporal dementia. European journal of neurology. 2012;19(6):911-7.
- 29] Cummings JL. Frontal-subcortical circuits and human behavior. Archives of neurology. 1993;50(8):873-80.
- 30] Perry RJ, Graham A, Williams G, Rosen H, Erzinçlioğlu S, Weiner M, et al. Patterns of frontal lobe atrophy in frontotemporal dementia: a

- volumetric MRI study. *Dementia and geriatric cognitive disorders*. 2006;22(4):278-87.
- 31] Zhou J, Greicius MD, Gennatas ED, Growdon ME, Jang JY, Rabinovici GD, et al. Divergent network connectivity changes in behavioural variant frontotemporal dementia and Alzheimer's disease. *Brain : a journal of neurology*. 2010;133(Pt 5):1352-67.
 - 32] Johnson JK, Diehl J, Mendez MF, Neuhaus J, Shapira JS, Forman M, et al. Frontotemporal lobar degeneration: demographic characteristics of 353 patients. *Archives of neurology*. 2005;62(6):925-30.
 - 33] Cousins K, Ash S, Olm CA, Grossman M. Longitudinal Changes in Semantic Concreteness in Semantic Variant Primary Progressive Aphasia (svPPA). 2018;5(6).
 - 34] Rankin KP, Baldwin E, Pace-Savitsky C, Kramer JH, Miller BL. Self awareness and personality change in dementia. *Journal of neurology, neurosurgery, and psychiatry*. 2005;76(5):632-9.
 - 35] Rohrer JD, Warren JD. Phenotypic signatures of genetic frontotemporal dementia. *Current opinion in neurology*. 2011;24(6):542-9.
 - 36] Goedert M, Crowther RA, Scheres SHW, Spillantini MG. Tau and neurodegeneration. *Cytoskeleton (Hoboken, NJ)*. 2024;81(1):95-102.
 - 37] Rascovsky K, Hodges JR, Knopman D, Mendez MF, Kramer JH, Neuhaus J, et al. Sensitivity of revised diagnostic criteria for the behavioural variant of frontotemporal dementia. *Brain : a journal of neurology*. 2011;134(Pt 9):2456-77.
 - 38] Knibb JA, Woollams AM, Hodges JR, Patterson K. Making sense of progressive non-fluent aphasia: an analysis of conversational speech. *Brain : a journal of neurology*. 2009;132(Pt 10):2734-46.
 - 39] Roytman M, Gordon ML, Franceschi AM. Nonfluent-Agrammatic Variant Primary Progressive Aphasia. In: Franceschi AM, Franceschi D, editors. *Hybrid PET/MR Neuroimaging: A Comprehensive Approach*. Cham: Springer International Publishing; 2022. p. 337-46.
 - 40] Sintini I, Duffy JR, Clark HM, Utianski RL, Botha H, Machulda MM, et al. Functional connectivity to the premotor cortex maps onto longitudinal brain neurodegeneration in progressive apraxia of speech. *Neurobiology of aging*. 2022;120:105-16.
 - 41] Shapiro NL, Todd EG, Billot B, Cash DM, Iglesias JE, Warren JD, et al. In vivo hypothalamic regional volumetry across the frontotemporal dementia spectrum. *NeuroImage Clinical*. 2022;35:103084.
 - 42] Tan YJ, Yong ACW, Foo JN, Lian MM, Lim WK, Dominguez J, et al. *C9ORF72* expansions are the most common cause of genetic frontotemporal dementia in a Southeast Asian cohort. 2023;10(4):568-78.
 - 43] de Boer SCM, Riedl L, van der Lee SJ, Otto M, Anderl-Straub S, Landin-Romero R, et al. Differences in Sex Distribution Between Genetic and Sporadic Frontotemporal Dementia. *Journal of Alzheimer's disease : JAD*. 2021;84(3):1153-61.
 - 44] Ratnavalli E, Brayne C, Dawson K, Hodges JR. The prevalence of frontotemporal dementia. *Neurology*. 2002;58(11):1615-21.
 - 45] Saxon JA, Thompson JC, Harris JM, Richardson AM, Langheinrich T, Rollinson S, et al. Cognition and behaviour in frontotemporal dementia with and without amyotrophic lateral sclerosis. 2020;91(12):1304-11.
 - 46] Ferrari R, Kapogiannis D, Huey ED, Momeni P. FTD and ALS: a tale of two diseases. *Current Alzheimer research*. 2011;8(3):273-94.
 - 47] Masrori P, Van Damme P. Amyotrophic lateral sclerosis: a clinical review. 2020;27(10):1918-29.
 - 48] Chen K, Gao T, Liu Y, Zhu K, Wang T, Zeng P. Identifying risk loci for FTD and shared genetic component with ALS: A large-scale multitrait association analysis. *Neurobiology of aging*. 2024;134:28-39.
 - 49] Mackenzie IR, Neumann M. Molecular neuropathology of frontotemporal dementia: insights into disease mechanisms from postmortem studies. *Journal of neurochemistry*. 2016;138 Suppl 1:54-70.
 - 50] Bird T, Knopman D, VanSwieten J, Rosso S, Feldman H, Tanabe H, et al. Epidemiology and genetics of frontotemporal dementia/Pick's disease. *Annals of neurology*. 2003;54 Suppl 5:S29-31.
 - 51] Pickering-Brown SM, Rollinson S, Du Plessis D, Morrison KE, Varma A, Richardson AM, et al. Frequency and clinical characteristics of progranulin mutation carriers in the Manchester frontotemporal lobar degeneration cohort: comparison with patients with *MAPT* and no known mutations. *Brain : a journal of neurology*. 2008;131(Pt 3):721-31.
 - 52] Liu L, Cui B, Chu M, Cui Y, Jing D, Li D, et al. The Frequency of Genetic Mutations Associated With Behavioral Variant Frontotemporal Dementia in Chinese Han Patients. *Frontiers in aging neuroscience*. 2021;13:699836.
 - 53] Wang Y, Mandelkow E. Tau in physiology and pathology. *Nature reviews Neuroscience*. 2016;17(1):5-21.
 - 54] Andreadis A. Tau gene alternative splicing: expression patterns, regulation and modulation of function in normal brain and neurodegenerative diseases. *Biochimica et biophysica acta*. 2005;1739(2-3):91-103.
 - 55] Rohrer J, Ryan B, Ahmed R. *MAPT*-Related Frontotemporal Dementia. In: Adam MP, Feldman J, Mirzaa GM, Pagon RA, Wallace SE, Bean LJH, et al., editors. *GeneReviews®*. Seattle (WA): University of Washington, Seattle. Copyright © 1993-2024, University of Washington, Seattle. *GeneReviews* is a registered trademark of the University of Washington, Seattle. All rights reserved.; 1993.
 - 56] Minaya MA, Mahali S, Iyer AK, Eteleeb AM, Martinez R, Huang G, et al. Conserved gene signatures shared among *MAPT* mutations reveal defects in calcium signaling. *Frontiers in molecular biosciences*. 2023;10:1051494.
 - 57] Takada LT. The Genetics of Monogenic Frontotemporal Dementia. *Dementia & neuropsychologia*. 2015;9(3):219-29.
 - 58] Strang KH, Golde TE, Giasson BI. *MAPT* mutations, tauopathy, and mechanisms of neurodegeneration. Laboratory investigation; a journal of technical methods and pathology. 2019;99(7):912-28.
 - 59] Sen A, Avsar O, Eliacik S, Uysal Tan F. Association between Alzheimer's disease, *MAPT* gene mutation and some biochemical biomarkers. *Nucleosides, nucleotides & nucleic acids*. 2024;1-10.
 - 60] Pîrșcoveanu DFV, Pirici I, Tudorică V, Bălșeanu TA, Albu VC, Bondari S, et al. Tau protein in neurodegenerative diseases - a review. *Romanian journal of morphology and embryology = Revue roumaine de morphologie et embryologie*. 2017;58(4):1141-50.
 - 61] Wang L, Chen J, Hu Y, Liao A, Zheng W, Wang X, et al. Progranulin improves neural development via the PI3K/Akt/GSK-3 β pathway in the cerebellum of a VPA-induced rat model of ASD. 2022;12(1):114.
 - 62] Yu CE, Bird TD, Bekris LM, Montine TJ, Leverenz JB, Steinbart E, et al. The spectrum of mutations in progranulin: a collaborative study screening 545 cases of neurodegeneration. *Archives of neurology*. 2010;67(2):161-70.
 - 63] Antonioni A, Raho EM, Lopriore P. Frontotemporal Dementia, Where Do We Stand? A Narrative Review. 2023;24(14).
 - 64] Paushter DH, Du H, Feng T, Hu F. The lysosomal function of progranulin, a guardian against neurodegeneration. 2018;136(1):1-17.
 - 65] Wu Y, Shao W, Todd TW, Tong J, Yue M, Koga S, et al. Microglial lysosome dysfunction contributes to white matter pathology and *TDP-43* proteinopathy in *GRN*-associated FTD. *Cell reports*. 2021;36(8):109581.
 - 66] Hodges JR. Frontotemporal dementia (Pick's disease): clinical features and assessment. *Neurology*. 2001;56(11 Suppl 4):S6-10.
 - 67] Masrori P, Beckers J, Gossye H, Van Damme P. The role of inflammation in neurodegeneration: novel insights into the role of the immune system in *C9ORF72* HRE-mediated ALS/FTD. *Molecular neurodegeneration*. 2022;17(1):22.
 - 68] DeJesus-Hernandez M, Mackenzie IR, Boeve BF, Boxer AL, Baker M, Rutherford NJ, et al. Expanded GGGGCC hexanucleotide repeat in noncoding region of *C9ORF72* causes chromosome 9p-linked FTD and ALS. *Neuron*. 2011;72(2):245-56.
 - 69] Gijssels I, Van Mossevelde S, van der Zee J, Sieben A, Engelborghs S, De Bleecker J, et al. The *C9ORF72* repeat size correlates with onset age of disease, DNA methylation and transcriptional downregulation of the promoter. *Molecular psychiatry*. 2016;21(8):1112-24.

- 70] Murphy NA, Arthur KC, Tienari PJ, Houlden H, Chiò A, Traynor BJ. Age-related penetrance of the *C9ORF72* repeat expansion. *Scientific reports*. 2017;7(1):2116.
- 71] Jackson JL, Finch NA, Baker MC, Kachergus JM, DeJesus-Hernandez M, Pereira K, et al. Elevated methylation levels, reduced expression levels, and frequent contractions in a clinical cohort of *C9ORF72* expansion carriers. 2020;15(1):7.
- 72] van der Ende EL, Jackson JL, White A, Seelaar H. Unravelling the clinical spectrum and the role of repeat length in *C9ORF72* repeat expansions. 2021;92(5):502-9.
- 73] Katisko K, Cajanus A, Korhonen T, Remes AM, Haapasalo A, Solje E. Prodromal and Early bvFTD: Evaluating Clinical Features and Current Biomarkers. *Frontiers in neuroscience*. 2019;13:658.
- 74] Gossye H, Engelborghs S, Van Broeckhoven C, van der Zee J. *C9ORF72* Frontotemporal Dementia and/or Amyotrophic Lateral Sclerosis. In: Adam MP, Feldman J, Mirzaa GM, Pagon RA, Wallace SE, Bean LJH, et al., editors. *GeneReviews*(®). Seattle (WA): University of Washington, Seattle. Copyright © 1993-2024, University of Washington, Seattle. *GeneReviews* is a registered trademark of the University of Washington, Seattle. All rights reserved.; 1993.
- 75] Moore KM, Nicholas J, Grossman M, McMillan CT, Irwin DJ, Massimo L, et al. Age at symptom onset and death and disease duration in genetic frontotemporal dementia: an international retrospective cohort study. *The Lancet Neurology*. 2020;19(2):145-56.
- 76] Braems E, Swinnen B, Van Den Bosch L. *C9ORF72* loss-of-function: a trivial, stand-alone or additive mechanism in C9 ALS/FTD? *Acta neuropathologica*. 2020;140(5):625-43.
- 77] Hao Z, Wang R, Ren H. Role of the *C9ORF72* Gene in the Pathogenesis of Amyotrophic Lateral Sclerosis and Frontotemporal Dementia. 2020;36(9):1057-70.
- 78] Geng Y, Liu C, Cai Q. Crystal structure of parallel G-quadruplex formed by the two-repeat ALS- and FTD-related GGGGCC sequence. 2021;49(10):5881-90.
- 79] Benajiba L, Le Ber I, Camuzat A, Lacoste M, Thomas-Anterion C, Couratier P, et al. TARDBP mutations in motoneuron disease with frontotemporal lobar degeneration. *Annals of neurology*. 2009;65(4):470-3.
- 80] Borroni B, Bonvicini C, Alberici A, Buratti E, Agosti C, Archetti S, et al. Mutation within TARDBP leads to frontotemporal dementia without motor neuron disease. *Human mutation*. 2009;30(11):E974-83.
- 81] Moreno F, Rabinovici GD, Karydas A, Miller Z, Hsu SC, Legati A, et al. A novel mutation P112H in the TARDBP gene associated with frontotemporal lobar degeneration without motor neuron disease and abundant neuritic amyloid plaques. *Acta neuropathologica communications*. 2015;3:19.
- 82] Ticozzi N, Ratti A, Silani V. Protein aggregation and defective RNA metabolism as mechanisms for motor neuron damage. *CNS & neurological disorders drug targets*. 2010;9(3):285-96.
- 83] Ling SC, Polymenidou M, Cleveland DW. Converging mechanisms in ALS and FTD: disrupted RNA and protein homeostasis. *Neuron*. 2013;79(3):416-38.
- 84] Charoniti E, Papastefanopoulou V, Florou-Hatziyiannidou C, Koros C, Stanitsa E, Papatriantafyllou JD, et al. TARDBP p.I383V, a recurrent alteration in Greek FTD patients. *Journal of the neurological sciences*. 2021;428:117566.
- 85] Manohar V, Crowley L, Sreedharan J. TARDBP-Related Amyotrophic Lateral Sclerosis-Frontotemporal Dementia. In: Adam MP, Feldman J, Mirzaa GM, Pagon RA, Wallace SE, Bean LJH, et al., editors. *GeneReviews*(®). Seattle (WA): University of Washington, Seattle. Copyright © 1993-2024, University of Washington, Seattle. *GeneReviews* is a registered trademark of the University of Washington, Seattle. All rights reserved.; 1993.
- 86] Skibinski G, Parkinson NJ, Brown JM, Chakrabarti L, Lloyd SL, Hummerich H, et al. Mutations in the endosomal ESCRTIII-complex subunit CHMP2B in frontotemporal dementia. *Nature genetics*. 2005;37(8):806-8.
- 87] van der Zee J, Urwin H, Engelborghs S, Bruylant M, Vandenberghe R, Dermaut B, et al. CHMP2B C-truncating mutations in frontotemporal lobar degeneration are associated with an aberrant endosomal phenotype in vitro. *Human molecular genetics*. 2008;17(2):313-22.
- 88] Urwin H, Ghazi-Noori S, Collinge J, Isaacs A. The role of CHMP2B in frontotemporal dementia. *Biochemical Society transactions*. 2009;37(Pt 1):208-12.
- 89] Waeggaert R, Dirrig-Grosch S, Parisot F, Keime C, Henriques A, Loeffler JP, et al. Longitudinal transcriptomic analysis of altered pathways in a CHMP2B(intron5)-based model of ALS-FTD. *Neurobiology of disease*. 2020;136:104710.
- 90] Ghanim M, Guillot-Noel L, Pasquier F, Jornea L, Deramecourt V, Dubois B, et al. CHMP2B mutations are rare in French families with frontotemporal lobar degeneration. *Journal of neurology*. 2010;257(12):2032-6.
- 91] van der Zee J, Van Broeckhoven C. Frontotemporal lobar degeneration—building on breakthroughs. *Nature Reviews Neurology*. 2014;10(2):70-2.
- 92] Harding O, Evans CS. ALS- and FTD-associated missense mutations in TBK1 differentially disrupt mitophagy. 2021;118(24).
- 93] Le Ber I, Camuzat A, Hannequin D, Pasquier F, Guedj E, Rovelet-Lecrux A, et al. Phenotype variability in progranulin mutation carriers: a clinical, neuropsychological, imaging and genetic study. *Brain : a journal of neurology*. 2008;131(Pt 3):732-46.
- 94] Ugbo C, West RJH. Lessons learned from CHMP2B, implications for frontotemporal dementia and amyotrophic lateral sclerosis. *Neurobiology of disease*. 2021;147:105144.
- 95] Grossman M, Seeley WW, Boxer AL. Frontotemporal lobar degeneration. 2023;9(1):40.
- 96] Yamanaka K, Sasagawa Y, Ogura T. Recent advances in p97/VCP/Cdc48 cellular functions. *Biochimica et biophysica acta*. 2012;1823(1):130-7.
- 97] Meyer H, Wehl CC. The VCP/p97 system at a glance: connecting cellular function to disease pathogenesis. *Journal of cell science*. 2014;127(Pt 18):3877-83.
- 98] Schütz AK, Rennella E, Kay LE. Exploiting conformational plasticity in the AAA+ protein VCP/p97 to modify function. *Proceedings of the National Academy of Sciences of the United States of America*. 2017;114(33):E6822-e9.
- 99] Columbres RCA, Chin Y, Pratti S, Quinn C, Gonzalez-Cuyar LF. Novel Variants in the VCP Gene Causing Multisystem Proteinopathy 1. 2023;14(3).
- 100] Schiava M, Ikenaga C. Clinical Classification of Variants in the Valosin-Containing Protein Gene Associated With Multisystem Proteinopathy. 2023;9(5):e200093.
- 101] Cirulli ET, Lasseigne BN, Petrovski S, Sapp PC, Dion PA, Leblond CS, et al. Exome sequencing in amyotrophic lateral sclerosis identifies risk genes and pathways. *Science (New York, NY)*. 2015;347(6229):1436-41.
- 102] Brenner D, Yilmaz R, Müller K, Grehl T, Petri S, Meyer T, et al. Hot-spot KIF5A mutations cause familial ALS. *Brain : a journal of neurology*. 2018;141(3):688-97.
- 103] Freischmidt A, Wieland T, Richter B, Ruf W, Schaeffer V, Müller K, et al. Haploinsufficiency of TBK1 causes familial ALS and frontotemporal dementia. *Nature neuroscience*. 2015;18(5):631-6.
- 104] McCauley ME, Baloh RH. Inflammation in ALS/FTD pathogenesis. 2019;137(5):715-30.
- 105] Kwiatkowski TJ, Jr., Bosco DA, Leclerc AL, Tamrazian E, Vandenberg CR, Russ C, et al. Mutations in the FUS/TLS gene on chromosome 16 cause familial amyotrophic lateral sclerosis. *Science (New York, NY)*. 2009;323(5918):1205-8.
- 106] Van Langenhove T, van der Zee J, Sleegers K, Engelborghs S, Vandenberghe R, Gijssels I, et al. Genetic contribution of FUS to frontotemporal lobar degeneration. *Neurology*. 2010;74(5):366-71.
- 107] Huey ED, Ferrari R, Moreno JH, Jensen C, Morris CM, Potocnik F, et al. FUS and TDP43 genetic variability in FTD and CBS. *Neurobiology of aging*. 2012;33(5):1016.e9-17.
- 108] Brenner D, Müller K, Lattante S, Yilmaz R, Knehr A, Freischmidt A, et al. FUS mutations dominate TBK1 mutations in FUS/TBK1 double-mutant ALS/FTD pedigrees. *Neurogenetics*. 2022;23(1):59-65.

- 109] Rea SL, Majcher V, Searle MS, Layfield R. SQSTM1 mutations--bridging Paget disease of bone and ALS/FTLD. *Experimental cell research*. 2014;325(1):27-37.
- 110] Rubino E, Rainero I, Chiò A, Rogaeva E, Galimberti D, Fenoglio P, et al. SQSTM1 mutations in frontotemporal lobar degeneration and amyotrophic lateral sclerosis. *Neurology*. 2012;79(15):1556-62.
- 111] van der Zee J, Van Langenhove T, Kovacs GG, Dillen L, Deschamps W, Engelborghs S, et al. Rare mutations in SQSTM1 modify susceptibility to frontotemporal lobar degeneration. *Acta neuropathologica*. 2014;128(3):397-410.
- 112] Foster AD, Rea SL. The role of sequestosome 1/p62 protein in amyotrophic lateral sclerosis and frontotemporal dementia pathogenesis. *Neural regeneration research*. 2020;15(12):2186-94.
- 113] Deng HX, Chen W, Hong ST, Boycott KM, Gorrie GH, Siddique N, et al. Mutations in UBQLN2 cause dominant X-linked juvenile and adult-onset ALS and ALS/dementia. *Nature*. 2011;477(7363):211-5.
- 114] Nguyen HP, Van Broeckhoven C, van der Zee J. ALS Genes in the Genomic Era and their Implications for FTD. *Trends in genetics* : TIG. 2018;34(6):404-23.
- 115] Higgins N, Lin B, Monteiro MJ. Lou Gehrig's Disease (ALS): UBQLN2 Mutations Strike Out of Phase. *Structure (London, England : 1993)*. 2019;27(6):879-81.
- 116] Fecto F, Esengul YT, Siddique T. Protein recycling pathways in neurodegenerative diseases. *Alzheimer's research & therapy*. 2014;6(2):13.
- 117] Safren N, Dao TP, Mohan HM, Huang C, Trotter B, Castañeda CA, et al. Pathogenic mutations in UBQLN2 exhibit diverse aggregation propensity and neurotoxicity. *Scientific reports*. 2024;14(1):6049.
- 118] Gorno-Tempini ML, Hillis AE, Weintraub S, Kertesz A, Mendez M, Cappa SF, et al. Classification of primary progressive aphasia and its variants. *Neurology*. 2011;76(11):1006-14.
- 119] de Souza LC, Hosogi ML. Diagnosis of frontotemporal dementia: recommendations of the Scientific Department of Cognitive Neurology and Aging of the Brazilian Academy of Neurology. 2022;16(3 Suppl 1):40-52.
- 120] Peet BT, Spina S. Neuroimaging in Frontotemporal Dementia: Heterogeneity and Relationships with Underlying Neuropathology. 2021;18(2):728-52.
- 121] Ricci M, Cimini A. Positron Emission Tomography (PET) and Neuroimaging in the Personalized Approach to Neurodegenerative Causes of Dementia. 2020;21(20).
- 122] Nakano S, Asada T, Yamashita F, Kitamura N, Matsuda H, Hirai S, et al. Relationship between antisocial behavior and regional cerebral blood flow in frontotemporal dementia. *NeuroImage*. 2006;32(1):301-6.
- 123] Kansal K, Mareddy M, Sloane KL, Minc AA, Rabins PV, McGready JB, et al. Survival in Frontotemporal Dementia Phenotypes: A Meta-Analysis. *Dementia and geriatric cognitive disorders*. 2016;41(1-2):109-22.
- 124] Gambogi LB, Guimarães HC. Treatment of the behavioral variant of frontotemporal dementia: a narrative review. 2021;15(3):331-8.
- 125] Panza F, Lozupone M, Seripa D, Daniele A, Watling M, Giannelli G, et al. Development of disease-modifying drugs for frontotemporal dementia spectrum disorders. 2020;16(4):213-28.
- 126] Logroscino G, Imbimbo BP, Lozupone M, Sardone R, Capozzo R, Battista P, et al. Promising therapies for the treatment of frontotemporal dementia clinical phenotypes: from symptomatic to disease-modifying drugs. 2019;20(9):1091-107.
- 127] Greaves CV, Rohrer JD. An update on genetic frontotemporal dementia. 2019;266(8):2075-86.
- 128] Tran H, Moazami MP, Yang H, McKenna-Yasek D, Douthwright CL, Pinto C, et al. Suppression of mutant C9ORF72 expression by a potent mixed backbone antisense oligonucleotide. 2022;28(1):117-24.
- 129] Donahue CP, Muratore C, Wu JY, Kosik KS, Wolfe MS. Stabilization of the tau exon 10 stem loop alters pre-mRNA splicing. *The Journal of biological chemistry*. 2006;281(33):23302-6.
- 130] Peacey E, Rodriguez L, Liu Y, Wolfe MS. Targeting a pre-mRNA structure with bipartite antisense molecules modulates tau alternative splicing. *Nucleic acids research*. 2012;40(19):9836-49.
- 131] Sevigny J, Uspenskaya O, Heckman LD, Wong LC, Hatch DA, Tewari A. Progranulin AAV gene therapy for frontotemporal dementia: translational studies and phase 1/2 trial interim results. 2024;30(5):1406-15.
- 132] Jadhav S, Avila J, Schöll M, Kovacs GG, Kövari E, Skrabana R, et al. A walk through tau therapeutic strategies. 2019;7(1):22.
- 133] Lee WC, Almeida S, Prudencio M, Caulfield TR, Zhang YJ, Tay WM, et al. Targeted manipulation of the sortilin-progranulin axis rescues progranulin haploinsufficiency. *Human molecular genetics*. 2014;23(6):1467-78.